

Evaluation of wheezing in the nonasthmatic patient

DAVID A. HOLDEN, MD AND ATUL C. MEHTA, MD

■ Wheezing is a nonspecific manifestation of airway obstruction. Even though bronchial asthma is the most common cause of wheezing, a variety of pulmonary and nonpulmonary conditions can present with this symptom. In recent years methacholine provocation challenge has simplified detection of bronchial asthma; however, establishing accurate diagnosis of other causes of wheezing is important because each condition requires specific treatment. This article describes a methodical approach to the diagnosis of wheezing in patients who are not asthmatic.

□INDEX TERMS: WHEEZING, AIRWAY OBSTRUCTION, BRONCHIAL ASTHMA □CLEVE CLIN J MED 1990; 57:345-352

VIRTUALLY ANY PROCESS that involves the tracheobronchial tree can produce wheezing, which is a nonspecific manifestation of airway obstruction. Causes of wheezing in the nonasthmatic include upper airway conditions such as angioedema, lower airway conditions such as chronic obstructive pulmonary disease (COPD), vascular causes such as pulmonary embolism, and unusual causes such as carcinoid syndrome or factitious asthma (*Table 1*). It is important to differentiate these conditions, because their treatments vary. This article presents a practical approach to the diagnosis of wheezing in patients who are suspected not to be asthmatic. Often these patients have failed to respond to aggressive asthma treatment or have negative provocation challenge tests for bronchospasm.

From the Department of Pulmonary Medicine, The Cleveland Clinic Foundation.

Address reprint requests to A.C.M., Department of Pulmonary Medicine, The Cleveland Clinic Foundation, One Clinic Center, 9500 Euclid Avenue, Cleveland, Ohio 44195.

HISTORY

Three issues need special attention in the history: the age at onset, the nature of the onset, and the course of symptoms.

Age at onset

The prevalence of bronchial asthma in children and adults is comparable.[1] Although it is the most common cause of wheezing in children, diagnostic confirmation is often difficult and empiric treatment is frequently instituted.

Wheezing in infants may signal the presence of congenital anomalies such as vascular rings, bronchopulmonary dysplasia, or bronchomalacia. In addition, cystic fibrosis can present as recurrent wheezing during childhood; a sweat chloride test may be indicated when wheezing is accompanied by gastrointestinal complaints or a suggestive family history.[2]

Foreign body aspiration may cause wheezing in children, especially between 6 months and 3 years of age. Foods are the substances most commonly aspirated, and in most cases a history of aspiration is obtainable.[3] Aspiration of large foreign bodies into the esophagus

Downloaded from www.ccjm.org on June 3, 2026. For personal use only. All other uses require permission.

TABLE 1
DIFFERENTIAL DIAGNOSIS OF WHEEZING

UPPER AIRWAYS
Vocal cord paralysis
Laryngeal neoplasms
Subglottic stenosis
Foreign body
Infection
Vincent's angina
Diphtheria
Epiglottitis
Laryngeal edema
Angioedema
Burns
Systemic lupus erythematosis
Laryngeal spasm
Infection
Tetany
Psychogenic
Laryngomalacia
Laryngeal web
LOWER AIRWAYS
Bronchial asthma
COPD (emphysema, chronic bronchitis)
Infections
Pyogenic
Tuberculosis
Fungal
Aspiration
Foreign body (esophagus)
Cystic fibrosis
Tracheal stenosis, tracheomalacia
Tracheal web
Mediastinal masses/lymphadenopathy
Allergic bronchopulmonary aspergillosis
Parasitic infestations
Löffler's syndrome
Bronchiolitis
Bronchiectasis
Chemical bronchitis
Endobronchial sarcoidosis
Endobronchial amyloidosis
Bronchopulmonary dysplasia
VASCULAR
Cardiac asthma
Pulmonary embolism
Vasculitis
Polyarteritis nodosa (PAN)
Allergic
Primary pulmonary hypertension
Vascular rings
Subglottic hemangioma
OTHER
Carcinoid syndrome
Factitious

such as coins, buttons, tacks, or bone can cause wheezing due to pressure on the airway. Adults may aspirate as well. In one review, 40% of the patients with esophageal foreign bodies were adults; meat and bone fragments were the objects most often aspirated.[4]

Although asthma can present at any age,[1] the onset of wheezing in a patient over age 40, particularly if it is localized, may be due to an intraluminal neoplasm. Wheezing is heard in 2% of patients with bronchogenic carcinoma; often the tumor is centrally located, causing compression of a large bronchus or, rarely, of the trachea.[5] Endobronchial metastasis from such malignancies as colon, renal, or thyroid carcinoma, seminoma, or melanoma may result in obstruction.[6]

Nature of onset

Patients with acute onset of wheezing should be questioned about prior episodes and response to therapy. A history compatible with aspiration, left ventricular failure, pneumonia, pulmonary embolism, or anaphylaxis should be sought. Recognition of risk factors for these conditions, such as a seizure disorder or alcoholism in aspiration pneumonia and prior surgery or prolonged bedrest in pulmonary embolism, leads to appropriate diagnostic testing.

The aspiration of gastric juices during the induction of anesthesia was first described by Mendelson.[7] It was invariably associated with the acute onset of wheezing, but subsequent infection was infrequent. The sputum produced by these patients can be pink and frothy, similar to that seen in pulmonary edema.

Other predisposing conditions may result in aspiration. In fact, most patients with aspiration pneumonia have an identifiable risk factor. In one study, more than 90% of such patients had a predisposing cause: for example, 24% had aspirated around a nasogastric tube, 39% had a motility disturbance of the esophagus, and 29% had a history of impaired consciousness.[8]

Pulmonary embolism may manifest itself as wheezing and tachypnea alone. Although 85% of patients with angiographically proven pulmonary embolism in one series had a decrement in FEV_1, few had audible wheezing.[9] A predisposing factor for embolization is identified in more than 90% of all patients with pulmonary embolism.[10] Patients who wheeze with pulmonary embolism often have a history of childhood asthma or an allergic diathesis.[11] Serotonin and histamine release from platelets, regional hypoxia, and hypocarbia all play a role in bronchoconstriction of the terminal airway in this condition.[12] Pulmonary embolism must be considered in an adult with wheezing and signs and symptoms of right heart failure or lower extremity venous abnormalities.[13]

The insidious onset of wheezing, particularly if associated with hemoptysis or hoarseness, may suggest bronchogenic carcinoma, tracheal tumor, or endobronchial metastasis. In the adult, the most common tracheal tumors are squamous cell carcinoma and adenoid cystic carcinoma.[14,15]

Downloaded from www.ccjm.org on June 3, 2026. For personal use only. All other uses require permission.

Clinical course

The clinical course of wheezing can be categorized as intermittent, persistent, or progressive. Patients with emphysema or chronic bronchitis may complain of either persistent or intermittent wheezing; these patients are older and have a significant smoking history.

Progressive wheezing associated with a history of allergic rhinitis, skin lesions, and abdominal pain is characteristic of the Churg-Strauss syndrome.[16] The disease may be diagnosed as asthma initially, but the development of severe eosinophilia, pulmonary infiltrates, and vasculitis identifies the syndrome.

A more fulminant course is seen in patients with idiopathic hypereosinophilic syndrome, 40% of whom have pulmonary involvement manifested by bronchospasm and pulmonary infiltrates.[17] A restrictive cardiomyopathy often develops from eosinophilic infiltration.

Diseases associated with intermittent wheezing most closely resemble bronchial asthma. Left ventricular dysfunction is a common imitator. An older patient with wheezing and a history of angina pectoris, myocardial infarction, or hypertension should be questioned about dyspnea, orthopnea, and pedal edema. Interstitial edema and vascular engorgement combine to increase airway resistance and residual lung volume in left ventricular dysfunction.[18]

A rare cause of intermittent wheezing is carcinoid syndrome—a triad of flushing, diarrhea, and cardiac valvular disease. Wheezing is reported in 25% of these patients.[19] Weight loss and abdominal pain may accompany the syndrome.

PHYSICAL EXAMINATION

To interpret the physical findings of the patient with wheezing, the difference between stridor, monophonic wheezing, and polyphonic wheezing must be understood. *Stridor* is a loud musical sound best heard over the trachea during inspiration when there is a large upper airway obstruction. *Wheezing* is akin to the vibrations of an uncoupled reed; wheezing sounds are produced during airflow as opposite walls of the bronchus close and open. Monophonic wheezes are heard during inspiration and expiration and suggest asthmatic bronchitis; polyphonic wheezes are heard during expiration and reflect dynamic compression of central bronchi, as in emphysema.[20]

Wheezing is common in patients with COPD. Marini et al,[21] in a study of 100 consecutive patients referred for spirometry, calculated a wheezing score based upon sitting and supine auscultation. Wheezes were heard in 48 of the 83 patients with obstruction. None of these showed a significant response to bronchodilators. Forced expiratory wheezing bore no relation to the extent of obstruction or to response to bronchodilator therapy. Wheezes were heard only in the supine position in 11 of the 48 patients.

Some clues to the source of wheezing in the nonasthmatic patient may be gained from the head and neck examination—for example, signs of upper respiratory tract infection, lymphadenopathy, thyromegaly, a scar from prior tracheostomy, and jugular venous distention. Other significant signs include an absent gag reflex in a patient who aspirates, and the lip and tongue swelling of angioedema. Skin findings should be noted, such as the palpable purpura of vasculitis, the waxy papules of amyloidosis, the linear erythema of visceral larva migrans, the flushing of carcinoid syndrome, or the venous congestion of deep vein thrombosis.

The presence of clubbing is important. Conditions that cause both clubbing and wheezing include bronchogenic carcinoma, congenital heart disease, and cystic fibrosis. Holsclaw[22] submits that asthma and clubbing in young adults are incompatible diagnoses. Bronchiectasis is the likely cause of clubbing in patients who carry a diagnosis of "asthmatic bronchitis" but actually have cystic fibrosis.

A complete cardiovascular examination should be performed in any patient who wheezes. Signs of left ventricular failure such as a palpable heave, a displaced apical impulse, or a third heart sound are well known. A loud pulmonic component of the second heart sound (P_2) may indicate pulmonary hypertension from embolic disease, parasitic infection, or COPD. Evidence of tricuspid valve insufficiency may support these findings or reflect carcinoid heart disease.

Wheezing may be accompanied by other physical disorders revealed by chest auscultation. For example, bibasilar rales may indicate cardiogenic pulmonary edema or bilateral pneumonia. Diffuse rales may be a result of noncardiogenic pulmonary edema. Decreased breath sounds and dullness to percussion heard with pleural fluid suggest malignancy, heart failure, or pulmonary embolism.

LABORATORY STUDIES

The laboratory study of particular interest in the evaluation of wheezing is the eosinophil count. Although asthma may be associated with mild eosinophilia, several other conditions are characterized by a higher

Downloaded from www.ccjm.org on June 3, 2026. For personal use only. All other uses require permission.

TABLE 2
CONDITIONS PRODUCING WHEEZING IN ASSOCIATION WITH PERIPHERAL EOSINOPHILIA

Allergic bronchopulmonary aspergillosis
Parasitic infestations
Ascaris lumbricoides
Ancylostoma duodenale or *Necator americanus*
Strongyloides stercoralis
Visceral larva migrans
Paragonimus westermani
Toxocara species
Dirofilaria immitis
Echinococcus granulosus
Schistosomiasis
Löffler's syndrome
Vasculitis
Polyarteritis nodosa
Allergic vasculitis (Churg-Strauss disease)
Wegener's granulomatosis
Hypereosinophilic syndrome
Tropical eosinophilia
Drug reactions
Nitrofurantoin
Sulphonamides
Penicillin
Methotrexate

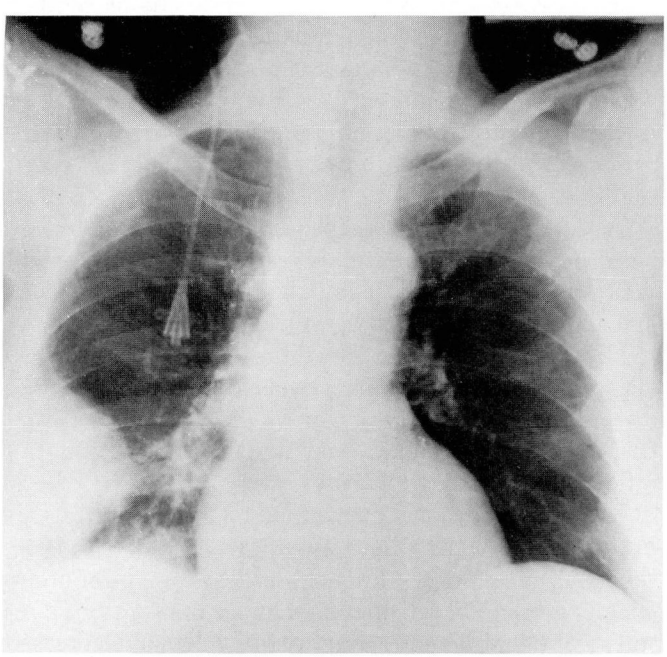

FIGURE 2. Chest radiograph reveals a peripheral dome-shaped density with apex pointed toward the hilum (Hampton's hump) and involving the right lung. The patient presented with dyspnea, pleuritic pain, hemoptysis, and wheezing.

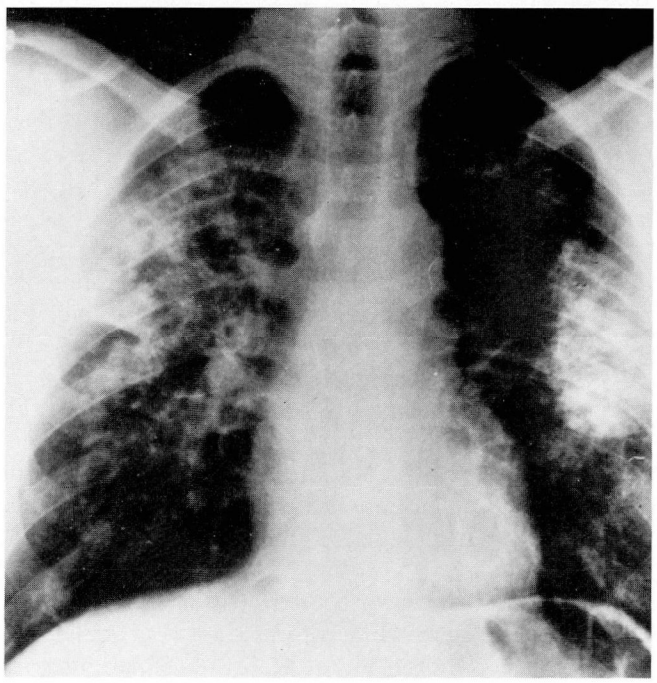

FIGURE 1. Posteroanterior view of the chest in a patient with chronic eosinophilic pneumonia reveals nodular infiltrates that involve peripheral midlung zones in the "reverse congestive heart failure" pattern.

eosinophil count (*Table 2*). Most of these conditions present with pulmonary infiltrates. A pre-existing diagnosis of asthma is reported in patients with allergic bronchopulmonary aspergillosis (ABPA), allergic vasculitis, and chronic eosinophilic pneumonia (CEP). The degree of eosinophilia will not help differentiate these causes, but very high levels have been noted in parasitic infections and in allergic vasculitis.[18] Although 40% of patients with hypereosinophilic syndrome have pulmonary disease, wheezing has not been reported as a predominant symptom.[23] Unlike CEP or Löffler's syndrome, the course in hypereosinophilic syndrome is progressive and fatal.[19] In patients with eosinophilia, appropriate historical data—including information on overseas travel, animal contacts, and drug therapy—as well as repeated sputum, urine, and stool examinations should be obtained. ABPA is diagnosed by a positive skin test and positive serum precipitins to *Aspergillus* species associated with elevated IgE levels. Evidence of central bronchiectasis on chest radiographs is supportive.

CHEST RADIOGRAPH

The chest radiograph is essential in the evaluation of wheezing in nonasthmatic patients. Findings may involve the parenchyma, airways, or mediastinum.

Downloaded from www.ccjm.org on June 3, 2026. For personal use only. All other uses require permission.

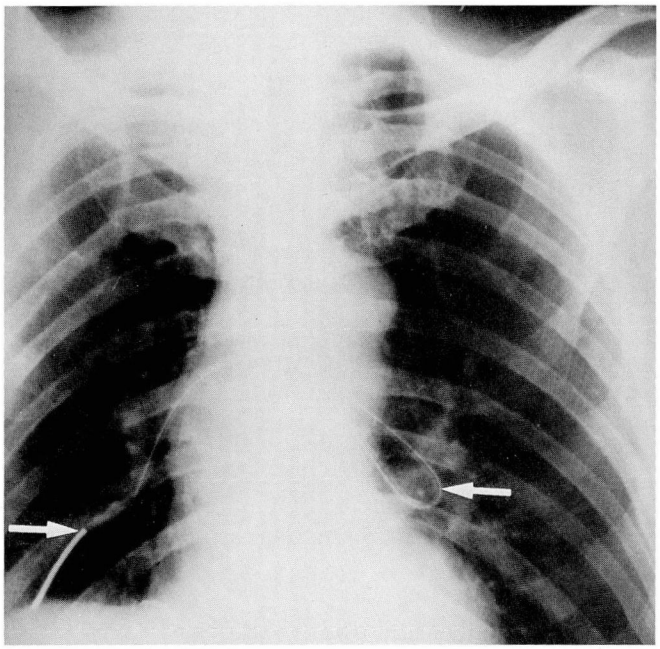

FIGURE 3. Chest radiograph reveals endobronchial placement of a Corpack feeding tube (arrows) as a cause of wheezing in a patient with bilateral vocal cord paralysis.

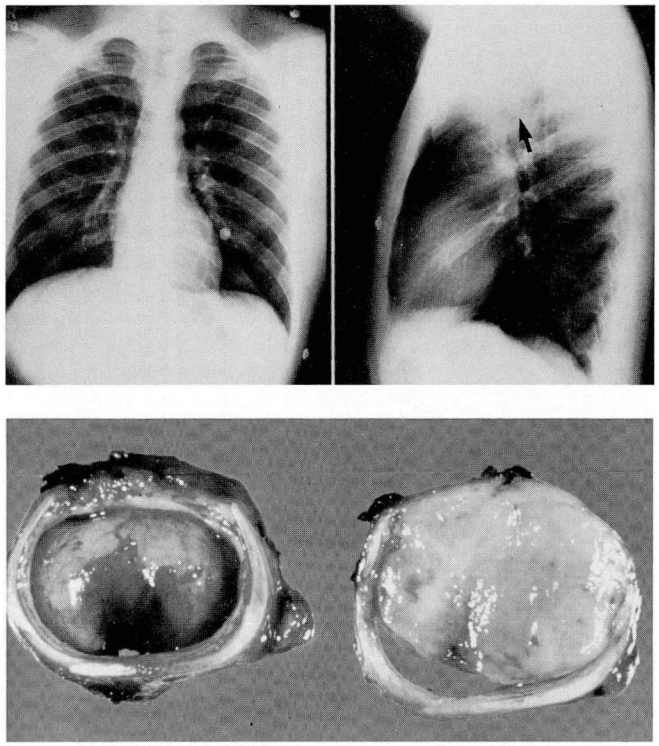

FIGURE 4A. Unremarkable posteroanterior chest radiograph of a 25-year-old male who presented with dyspnea and wheezing. FIGURE 4B. Lateral chest radiograph of the same patient reveals a lesion (arrow) involving lower tracheal air column. FIGURE 4C. Macroscopic examination of the same lesion following tracheal resection and reconstruction (microscopic diagnosis: plasma cell granuloma).

Parenchyma

Transient, migratory, single or multiple nonsegmental areas of consolidation in a patient with peripheral eosinophilia suggest Löffler's syndrome. Nodular infiltrates that involve the peripheral midlung zones and spare the apices and bases, referred to as a "reverse congestive heart failure" pattern, are seen in CEP (*Figure 1*).

If a patient has aspirated in the supine position, the alveolar infiltrates involve the superior segments of the lower lobes, the posterior segments of the upper lobes, or both. The presence of cardiomegaly, cephalization of blood flow, bilateral pleural effusions, and Kerley B lines are diagnostic of congestive heart failure.

In patients with pulmonary embolism, the chest radiograph is usually normal. The next most common finding is either an elevated hemidiaphragm or parenchymal consolidation.[24] A dome-shaped density that is pleural-based and points to the hilum, called Hampton's hump (*Figure 2*), strongly suggests pulmonary embolism, but any infiltrate that abuts the pleural surface can be associated with pulmonary embolism.[25]

Airway abnormalities

A radio-opaque foreign body is easily detected on a plain chest radiograph (*Figure 3*). Atelectasis or partial collapse of the lung suggests a foreign body or an airway neoplasm. Partial airway obstruction by a foreign body can produce ipsilateral hyperlucent lung syndrome. On occasion, mediastinal shift is also present and is best appreciated when inspiratory and expiratory radiographs are compared.

Overall, the chest radiograph contributes to the diagnosis of a bronchial foreign body in 85% of cases.[2] Since a large airway lesion can be present without collapse or hyperinflation, a careful review of the airways should be performed in all cases; sudden cut-off of the air column suggests an airway lesion (*Figures 4 A,B,C*). Upper airway lesions such as tracheal stenosis, goiter, or epiglottitis may become evident with appropriate studies such as tracheal computed tomography (CT) or lateral neck views.

An acute attack of ABPA has typical radiographic signs. For example, mucoid impaction in ABPA can produce a "gloved finger" or "Y sign"; both terms describe

Downloaded from www.ccjm.org on June 3, 2026. For personal use only. All other uses require permission.

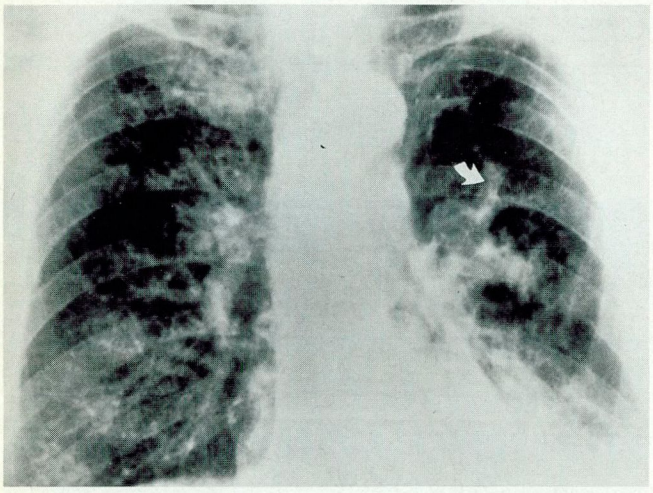

FIGURE 5. Finger-shaped infiltrate (finger glove or "Y" sign) involving the left hilum in a patient with ABPA. Infiltrates are mucoid impactions in proximal airways.

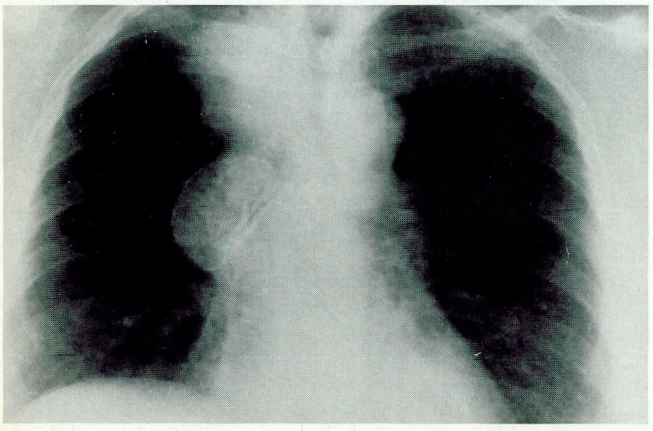

FIGURE 7. Posteroanterior radiograph of the chest reveals large calcified right hilar lymph node that caused airway obstruction in a patient with Hodgkin's disease following radiation therapy.

the fingerlike infiltrates emanating from the hilum (*Figures 5, 6A, and 6B*). Collapse of one or more lobes of the lung may occur during an acute event, while proximal bronchiectasis is often observed in the quiescent stage. Similar radiographic findings have been seen in patients who have cystic fibrosis with hyperinflation and fibrotic changes. The diagnosis of bronchiectasis can be confirmed by bronchography or chest CT.[26]

Vascular rings or slings produce signs of airway obstruction in infants. The diagnosis requires a high degree of suspicion, as chest radiograph and bronchoscopy findings are subtle. A double or right-sided aortic arch or a late take-off of the left pulmonary artery produces such constriction.

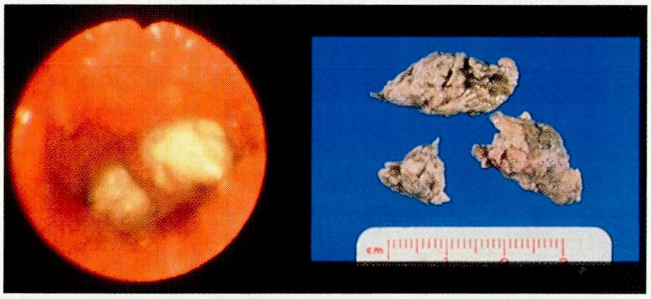

A,B

FIGURE 6A. Endoscopic view of mucoid impaction involving proximal airways in a patient with ABPA. FIGURE 6B. Gross examination of mucous plugs following extraction.

Hilar and mediastinal abnormalities

Although plain radiographs may suggest a hilar or mediastinal abnormality (*Figure 7*), CT of the mediastinum is often required to define the underlying pathology. CT is particularly helpful in evaluating the lymphadenopathy of lymphoma, sarcoidosis, substernal goiter, obstructive broncholiths, bronchogenic cysts, or fibrosing mediastinitis.

PULMONARY FUNCTION STUDIES

A pulmonary function study is indicated for most patients being evaluated for wheezing. Patients with conditions other than bronchial asthma, such as acute bronchitis, can respond well to bronchodilator therapy. Methacholine challenge testing can uncover underlying asthma in patients whose spirometry values are normal.

The configuration of the flow-volume loop can reflect the site and nature of large airway obstruction. A reduction in inspiratory flow rate with a normal expiratory flow rate is seen in conditions that produce variable extrathoracic upper airway obstruction, such as bilateral vocal cord paralysis. During inspiration, the relative positive atmospheric pressure adds to the obstruction. On the other hand, positive intrapleural pressure during exhalation reduces peak as well as midexpiratory flow rates in patients with variable intrathoracic airway obstruction, while inspiratory flow rates are maintained (*Figure 8*). Large, fixed upper airway obstruction such as tracheal stenosis would reduce expiratory as well as inspiratory flow rates (*Figure 9*). The FEV_1 is an insensitive measure of large airway obstruction because three-

Downloaded from www.ccjm.org on June 3, 2026. For personal use only. All other uses require permission.

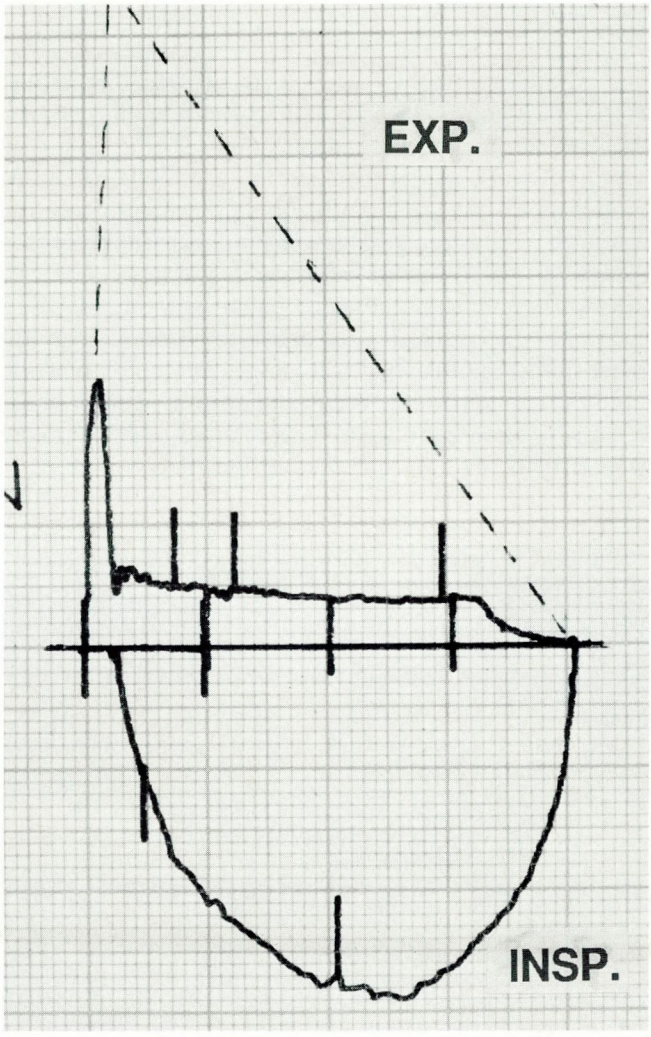

FIGURE 8. Flow-volume loop demonstrates flattening of the expiratory curve, which suggests variable intrathoracic upper airway obstruction; the patient has tracheal stenosis from healed endobronchial tuberculosis. *EXP = expiration; ENSP = inspiration.*

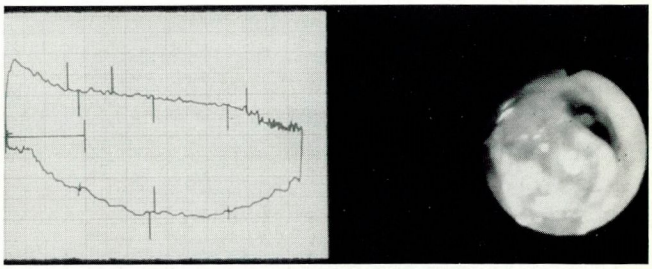

FIGURE 9. Flow-volume loop demonstrates characteristic configuration for a fixed upper airway obstruction (left) in a patient with adenocarcinoma that produced approximately 95% tracheal obstruction (right).

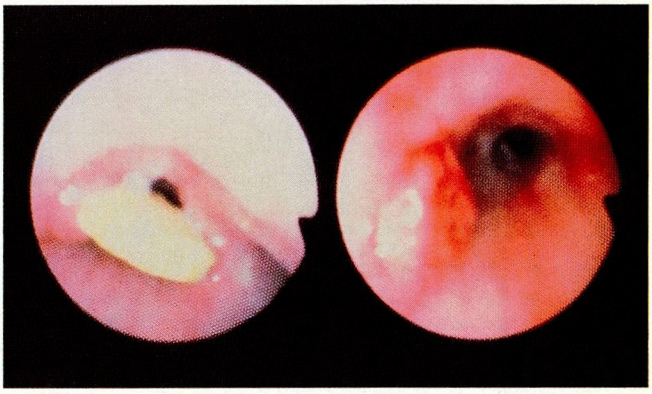

FIGURE 10. Endoscopic view reveals a pill lodged in the bronchus intermedius (right) of an elderly woman who presented with a wheeze localized to the right. Following removal of the pill with the flexible bronchoscope, granulation tissue is seen to involve the airway.

fourths of the expired volume has a flow rate limited by the dynamic compression of the small airways; the FEV_1 remains greater than 90% of predicted until the airway is compressed to less than 6 mm in diameter.[27]

ENDOSCOPIC EXAMINATION

If the above tests fail to establish a diagnosis for the cause of wheezing, an endoscopic examination is required; its importance cannot be overemphasized. The advent of the fiberoptic bronchoscope has simplified this evaluation and significantly reduced the morbidity associated with the procedure. It can be performed on an outpatient basis using local anesthesia.

Bronchoscopy allows direct visualization of the obstructing lesion and collection of tissue for biopsy. Moreover, it is easy to debulk large endobronchial lesions with forceps or laser instruments and to remove foreign bodies through either the flexible or rigid bronchoscope[28,29] (*Figure 10*).

FACTITIOUS ASTHMA

Factitious asthma can escape detection even with thorough investigation. The patient is typically a young woman with a history of hospital employment or psychiatric illness.[30] The "attacks" are associated more with stridor than with wheezing, and the airway sounds are best heard over the larynx.[31] The symptoms are caused

Downloaded from www.ccjm.org on June 3, 2026. For personal use only. All other uses require permission.

by self-induced glottic dysfunction in which the cords remain adducted during the entire respiratory cycle.[32] Normal laryngoscopy findings were noted in the first cases reported,[33] but if endoscopy is performed during an episode of wheezing or stridor, adduction of the vocal cords may be observed. In contrast to bronchial asthma, arterial blood gases and lung residual volumes are normal during the attacks.[30] The flow-volume loop may show variable extrathoracic obstruction if obtained during the attack only.[32]

Factitious asthma is refractory to conventional treatments, including high-dose steroids. Often there is a history of repeated intubations or tracheostomies. An excellent response to speech therapy was noted in one study.[32]

SUMMARY

Although bronchial asthma is the most common cause of wheezing, nonasthmatic patients of all ages may wheeze. For successful management of this common symptom and correct diagnosis of the underlying cause, a methodical approach and thorough evaluation are required. The history may be diagnostic, but emphasis may need to be placed on the physical examination and ancillary studies. Flow-volume loops can point to a specific site and type of lesion. CT and bronchoscopy may be particularly helpful when the cause is uncertain. It is not unusual for a patient with a condition that mimics asthma to have been treated aggressively with steroids, with little benefit and significant side effects.

REFERENCES

1. William SH, McNicol KN. Prevalence, natural history, and relationship of wheezy bronchitis and asthma in children: an epidemiological study. Br Med J 1969; **4**:321–325.
2. Kolski G, Lillie MA, Anolik R. Three puzzling wheezes that were not asthma. Hosp Pract 1981; **11**:153–156,161,165.
3. Blazer S, Nareh Y, Friedman A. Foreign body in the airway: a review of 200 cases. Am J Dis Child 1980; **134**:68–71.
4. Brooks JW. Foreign bodies in air and food passages. Ann Surg 1972; **175**:720–732.
5. Hyde L, Hyde CI. Clinical manifestations of lung cancer. Chest 1974; **65**:299–306.
6. Braman SS, Whitcomb ME. Endobronchial metastasis. Arch Intern Med 1975; **135**: 543–547.
7. Mendelson CL. The aspiration of stomach contents into the lungs during obstetric anesthesia. Am J Obstet Gynecol 1946; 52:191-205.
8. Arms PA, Diines DE, Tintsman TC. Aspiration pneumonia. Chest 1974; **65**: 136–139.
9. Sasahara AA, Cannila JE, Morse RL, et al. Clinical and physiological studies in pulmonary thromboembolism. Am J Cardiol 1967; **20**:10–20.
10. Bell WR, Simon TL, Demets DL. The clinical features of submassive and massive pulmonary embolism. Am J Med 1977; **62**:355–360.
11. Olazabal F, Roman-Irizarry LA, Oms JD, et al. Pulmonary emboli masquerading as asthma. N Engl J Med 1968; **278**:999–1001.
12. Moser KM. Pulmonary embolism. Am Rev Respir Dis 1977; **115**:829–852.
13. Windebank WJ, Boyd G, Moran F. Pulmonary thromboembolism presenting as asthma. Br Med J 1973; **1**:90–94.
14. Weber AL, Grillo HC. Tracheal tumors. Radiol Clin North Am 1977; **16(2)**:227–246.
15. Baydur A, Gottlieb LS. Adenoid cystic carcinoma of the trachea masquerading as asthma. JAMA 1975; **234**:829–831.
16. Lanham JG, Elkon KB, Pusey CD, Hughes GR. Systemic vasculitis with asthma and eosinophilia: a clinical approach to the Churg-Strauss syndrome. Medicine 1984; **63**:65–81.
17. Fauci AS. Moderator, NIH Conference. The idiopathic hypereosinophilic syndrome. Ann Intern Med 1983; **97**:78–95.
18. Hales CA, Kazemi H. Pulmonary function after uncomplicated myocardial infarction. Chest 1977; **72**:350–358.
19. Aldrich LB, Maattari R, Vinik AI. Distinguishing features of idiopathic flushing and carcinoid syndrome. Arch Intern Med 1988; **148**:2614–2618.
20. Fongacs P. The functional basis of pulmonary sounds. Chest 1978; **73**:399–405.
21. Marini JJ, Pearson DJ, Hudson LD, Lakshminarayan S. The significance of wheezing in chronic airflow obstruction. Am Rev Respir Dis 1979; **120**: 1069–1072.
22. Holsclaw DS. Cystic fibrosis: overview and pulmonary aspects in young adults. Clin Chest Med 1980; **1(3)**:407–423.
23. Chusid MJ, Dale DC, West BC, Wolff SM. The hypereosinophilic syndrome. Medicine 1975; **54**:1–27.
24. Sasahara AA, Hyers TM, Cole C, et al. eds. The urokinase pulmonary embolism trial: a national cooperative study. Circulation 1973; **47**:1–100(S).
25. Moser KM. Pulmonary embolism. [In] Murray JF, Nadel JA eds. Textbook of Respiratory Medicine. Philadelphia, W.B. Saunders, 1988.
26. Muller NL, Bergin CJ, Ostrow DN, Nichols DM. Role of computed tomography in the recognition of bronchiectasis. AJR 1984; **143**:971–976.
27. Kryger M, Bode F, Antic R, Anthonisen N. Diagnosis of obstruction of the upper and central airways. Am J Med 1976; **61**:85–93.
28. Cavaliere S, Foccoli P, Farina PL. Nd:YAG laser bronchoscopy: a five-year experience with 1,396 applications in 1,000 patients. Chest 1988; **94**:15–21.
29. Desai SJ, Mehta AC, Medendorp SV, Golish JA, Ahmad M. Survival experience following Nd:YAG laser photoresection for primary bronchogenic carcinoma. Chest 1988; **94**:939–944.
30. Downing ET, Braman SS, Fox MJ, Currao WM. Factitious asthma. JAMA 1982; **248**:2878–2882.
31. Rodenstein RO, Francis C, Stanescu DC. Emotional laryngeal wheezing: a new syndrome. Am Rev Respir Dis 1983; **127**:354–356.
32. Christopher KL, Wood RP, Eckert C, et al. Vocal cord dysfunction presenting as asthma. N Engl J Med 1983; **308**:1566–1570.
33. Cormier YF, Camus P, Desmeules MJ. Nonorganic acute upper airway obstruction. Am Rev Respir Dis 1980; **121**:147–150.

Downloaded from www.ccjm.org on June 3, 2026. For personal use only. All other uses require permission.