Received: 9 June 2022 | Revised: 4 August 2022 | Accepted: 6 August 2022

DOI: 10.1111/bcp.15490

THEMED ISSUE REVIEW

Drugs and the skin: A concise review of cutaneous adverse drug reactions

Blanca R. Del Pozzo-Magaña[1] | Carmen Liy-Wong[2]

[1]Department of Pediatrics, Division of Pediatric Clinical Pharmacology, Children's Hospital of Western Ontario, Western University, London, ON, Canada

[2]Department of Pediatrics, Division of Dermatology and Rheumatology, Children's Hospital of Eastern Ontario, University of Ottawa, Ottawa, ON, Canada

Correspondence
Blanca R. Del Pozzo-Magana MD,
800 Commissioners Road East, Room: B1-177,
London, ON, N6A 5W9, Canada.
Email: brdelpozzo@gmail.com

Drug-induced skin disease or cutaneous adverse drug reactions (CADRs) are terms that encompass the clinical manifestations of the skin, mucosae and adnexa induced by a drug or its metabolites. The skin is the organ most frequently affected by drug reactions, which may affect up to 10% of hospitalized patients and occur in 1–3% of multimedicated patients. Most CADRs are mild or self-resolving conditions; however, 2–6.7% of could develop into potentially life-threatening conditions. CADRs represent a heterogeneous field and can be diagnostically challenging as they may potentially mimic any dermatosis. Currently, there are between 29–35 different cutaneous drug-reaction patterns reported ranging from mild dermatitis to an extensively burnt patient. The most frequently reported are maculopapular rash, urticaria/angioedema, fixed drug eruption and erythema multiforme. Less common but more severe patterns include erythroderma, drug reaction with eosinophilia and systemic symptoms, and Stevens–Johnson syndrome/toxic epidermal necrolysis spectrum. Almost any drug can induce a CADR, but antibiotics, nonsteroidal anti-inflammatory drugs and antiepileptics are the most frequently involved. Different mechanisms are involved in the pathogenesis of CADRs, although in some cases, these remain still unknown. CADRs could be classified in different ways: (i) type A (augmented) or type B (bizarre); (ii) immediate or delayed; (iii) immune-mediated or nonimmune-mediated; (iv) nonsevere or life-threatening; and (v) by their phenotype, including exanthematous, urticarial, pustular and blistering morphology. Recognizing a specific CADR will mostly depend on the ability of the physician to perform a detailed clinical examination, the proper description of the morphology of the skin lesions and supporting laboratory and/or skin biopsy findings.

KEYWORDS
cutaneous adverse drug reaction, drug hypersensitivity syndromes, drug-induces skin disease

1 | INTRODUCTION

The skin, also known as the integumentary system, is the largest organ of the human body and has many essential functions, including temperature and fluid balance regulation, and vitamin D production and absorption. It also functions as a sense organ and protects the body from external insults such as physical and chemical damage and different microorganisms. In addition, skin immune cells such as myeloid and lymphoid immune cells act as an outpost for immune surveillance body protection.[1]

An adverse drug reaction (ADR) is defined as a noxious and unintended response to a drug that occurs at usual doses in a person. ADRs represent a health problem worldwide and occur in as many as 0.1–1% of every patient taking systemic medications. These impact patient treatment and health-related quality of life and represent a high cost for the healthcare systems.[2]

 © 2022 British Pharmacological Society.

Cutaneous ADRs (CADRs) are undesirable effects of a drug manifested in the skin and its adnexa (nails, hair, glands). Skin is the organ most frequently affected by drug reactions (45%). The prevalence of CADRs varies from 1 to 3% among adult patients, while around 2.5% of children treated with a drug will experience CADRs.[3,4] Overall, CADRs affect up to 10% of all hospitalized patients. Fortunately, most CADRs are mild or self-resolving conditions; however, 2–6.7% of cutaneous reactions can develop into severe and potentially life-threatening clinical syndromes. These severe cutaneous adverse reactions (SCARs) have a global frequency of 0.4–1.2 cases per million per year but their incidence varies depending on the population and the trigger drug.[5] Zhang *et al*, have recently stated that the estimated incidence of SCARs could range from 1 in 1000 to 1 in 10 000 drug exposures.[6,7]

Clinical presentation of CADRs vary widely. Currently, around 29–35 cutaneous drug-reaction patterns have been reported. Most common morphologies include urticaria with and without angioedema, maculopapular drug eruptions, fixed drug eruption, erythema multiforme (EM) and vasculitis. Less common but more severe patterns include erythroderma, drug reaction with eosinophilia and systemic symptoms (DRESS), and Stevens–Johnson syndrome (SJS)/toxic epidermal necrolysis (TEN) spectrum, acute generalized exanthematous pustulosis (AGEP) and serum sickness (SS).[7–10] The frequency of these dermatological patterns may vary depending on the population and the setting of the study, as well as the accuracy of the diagnosis. Unfortunately, the lack of knowledge or interest in CADRs has led to overdiagnosis or misdiagnosis of certain conditions. For example, approximately 10% of all US patients have been labelled as allergic to penicillin; however, <2% of this population is truly allergic.[11] By contrast, a study has shown that >65% of cases reported in the literature as drug-induced EM did not fulfil the diagnostic criteria for this condition, and those that clinically were consistent with EM did not provide valid evidence of drug causality.[12] Similarly, several studies have demonstrated that only a small percentage of patients diagnosed with SJS/TEN have in fact the clinical features required to make the diagnosis.[13,14]

Practically any drug by any route can induce a skin reaction, including over-the-counter medications, *natural products*, home remedies and traditional medicine. Interestingly, a single drug can induce different dermatological patterns with diverse pathophysiology. In contrast, a specific cutaneous drug reaction may be caused by drugs with different chemical structures and/or mechanisms of action. The most common trigger drugs reported in the literature include antimicrobials, analgesic, anti-inflammatory/antipyretic drugs, anticonvulsants, antipsychotics and vaccines, among many others[15–17]; however, the majority of these studies do not include cutaneous adverse reactions associated with side effects of medications including chemotherapy or biological therapies.

In general, any person could develop a CADR; however, the risk factors primarily associated with these conditions include female sex, age <60 years, hospitalization, obesity and immune dysregulation.[18] Likewise, the risk of developing a CADR increases with the number of drugs taken, concomitant viral infections, genetic variations in the metabolism of a drug and human leucocyte antigens (HLA) association.[19] For example, several authors have described genetic associations between specific HLAs and an increased risk of developing SCARs in specific populations such as HLA-A*31 and carbamazepine-induced DRESS in the north African population and HLA-B*58:01 and DRESS and SJS/TEN in east Asians treated with allopurinol.[20,21]

2 | CLASSIFICATION OF CADRS

Due to their wide variety, CADRs classification can be challenging and sometimes confusing. There are several ways to classify these conditions including by their morphology, time of presentation, severity, pathophysiology or the classical ADR classification described by Rawlins and Thompson in 1977 (type A, B).[22] These classifications are different between them but not exclusionary (Figure 1). Thus, hives developed a couple of minutes after amoxicillin exposure could be classified as a type B, Immediate, mild, immunoglobulin (Ig)E-mediated hypersensitivity reaction, while hand–foot syndrome (HFS; palmar–

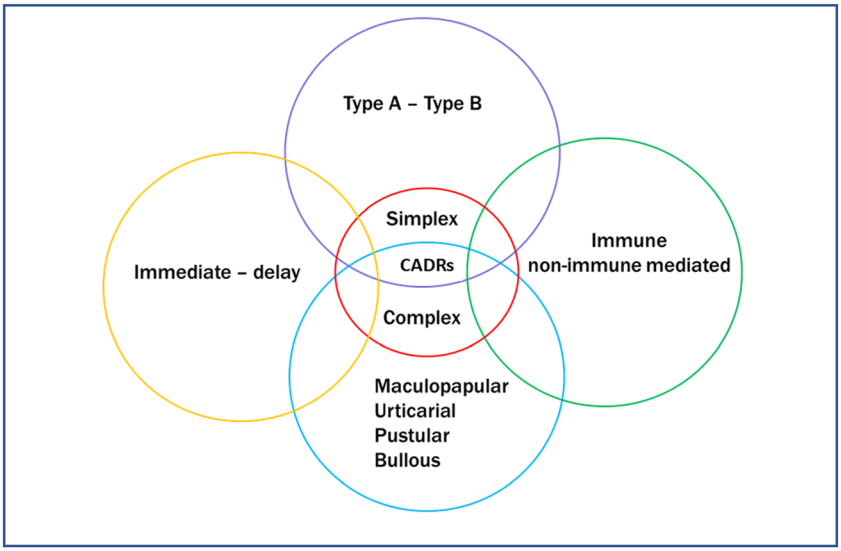

FIGURE 1 Cutaneous adverse drug reaction (CADR) classification types

13652125, 2024, 8, Downloaded from https://bpspubs.onlinelibrary.wiley.com/doi/10.1111/bcp.15490, Wiley Online Library on [18/08/2025]. See the Terms and Conditions (https://onlinelibrary.wiley.com/terms-and-conditions) on Wiley Online Library for rules of use; OA articles are governed by the applicable Creative Commons License

plantar erythrodysaesthesia) associated with 5-fluorouracil could be classified as type A, delayed, severe, nonimmune reaction.

The majority of the CADRs (around 80%) are predictable (type A). These are the consequence of the drug's mechanism of action, usually dose-dependent and not immune-mediated; while the remaining 20% or type B (idiosyncratic or bizarre) are usually unpredictable as they are not related to the pharmacological effect of a drug and could be immune or not immune-mediated.[19] Regarding the time of presentation CADRs can be divided into immediate and delayed reactions. Immediate reactions occur within minutes or hours of drug exposure, while delayed type usually takes several days or even weeks to develop.[7]

2.1 | Type A

Type A reactions are predictable, dose-related toxicities, often identified in preclinical or clinical trials, and usually occur in overdose settings. As the dose of the administered agent increases, the risk of adverse event increases with it, in accordance with the pharmacological profile of the agent. Type A adverse effects or side effects may also be characterized as drug toxicities. Some examples are shown in Figure 2.

2.2 | Chemotherapy-related cutaneous toxicity

Chemotherapy-related cutaneous toxicity includes generalized rashes or site-specific toxicity such as mucositis, alopecia, nail changes, extravasation reactions or HFS. Most of the toxicity is reversible with chemotherapy dose reductions or delays. Newer nonchemotherapeutic targeted therapies such as epidermal growth factor receptor inhibitors (e.g., gefitinib, cetuximab, erlotinib) may also be associated with cutaneous toxicity and can be distressing for patients. Recent data suggest that skin toxicity associated with these agents may correlate with efficacy. Early recognition and treatment of the toxicity facilitates good symptom control, prevents treatment-related morbidity and allows continuation of anticancer therapy.[23]

2.2.1 | HFS

HFS is known as palmar–plantar erythrodysaesthesia syndrome, acral erythema, Burgdorf's syndrome and more recently grouped with the so-called toxic erythema of chemotherapy syndromes. It is a relatively common skin reaction to chemotherapy and is characterized by palmoplantar numbness, tingling or burning pain accompanied by sharply demarcated erythema with or without oedema, cracking or desquamation. In patients with skin of colour may present macular hyperpigmentation instead of erythema.[24,25] The drugs that are most associated with HFS are pegylated liposomal doxorubicin, docetaxel and fluoropyrimidines such as intravenous 5-fluorouracil, capecitabine and S-1. Clinical symptoms recur with repeated exposure and diminish after the drug is discontinued.[26] Although HFS is not considered life threatening, it can be debilitating and interfere with daily activities, compromising the patient's health quality of life.[27,28]

The pathogenesis of HFS is poorly understood but it is believed that this toxic reaction is due to the local accumulation of the drug

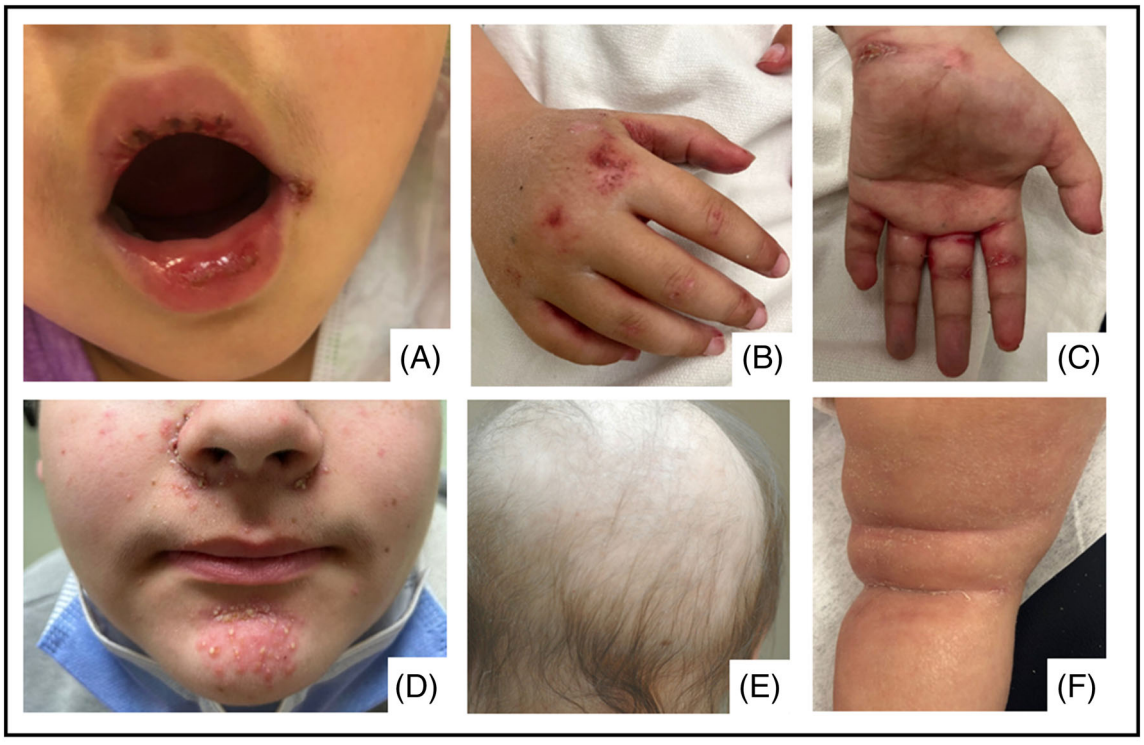

A) Mucositis due to methotrexate, B and C) Hand foot syndrome, D) Acneiform eruption due to trametinib, E) Alopecia due docetaxel, F) Eczematous eruption due to trametinib.

FIGURE 2 Cutaneous adverse drug reactions. type A

13652125, 2024, 8, Downloaded from https://bpspubs.onlinelibrary.wiley.com/doi/10.1111/bcp.15490, Wiley Online Library on [18/08/2025]. See the Terms and Conditions (https://onlinelibrary.wiley.com/terms-and-conditions) on Wiley Online Library for rules of use; OA articles are governed by the applicable Creative Commons License

with consequent degeneration and necrosis of the sweat glands as they are highly vascular and have higher rates of division of skin cells than other skin areas.[28–30]

2.2.2 | Bleomycin-induced flagellate dermatitis

Bleomycin-induced flagellate dermatitis is a dose-dependent reaction that usually occurs with total doses above 100 U. The incidence of developing flagellate dermatitis and consequent hyperpigmentation after receiving bleomycin treatment is reported between 8 and 22%. The characteristic symptoms are pruritic linear hyperpigmentation, arranged in a flagellate pattern and developing particularly on the trunk. The precise mechanism of this side effect remains unknown, but it is believed that the lack of bleomycin hydrolase enzyme in the skin, which inactivates bleomycin, results in bleomycin accumulation. Subsequent skin trauma (e.g. scratching) induces the development of skin lesions as it increases blood flow to the affected area causing more drug accumulation. The lesions usually diminish 3–4 months after the interruption of the bleomycin treatment.[31,32]

2.2.3 | Chemotherapy-induced oral mucositis

This is a common complication of cancer chemotherapy. It results from a complex interaction of local tissue damage, the local oral environment, the patient's level of myelosuppression and the patient's intrinsic genetic predisposition (e.g., single nucleotide polymorphisms) to develop oral mucositis. It begins 5–10 days after the initiation of chemotherapy and lasts 7–14 days. Chemotherapy-induced oral mucositis causes the mucosal lining of the mouth to atrophy and break down, forming ulcers. The most common chemotherapeutic agents that cause oral mucositis are methotrexate, 5-fluorouracil and cytarabine.[33]

2.2.4 | Drug-induced hair loss

Drugs cause hair loss by 2 major mechanisms: inducing an abrupt cessation of mitotic activity in rapidly dividing hair matrix cells (anagen effluvium) or precipitating the follicles into premature rest (telogen effluvium).[34] In the former, hair loss usually occurs within days to weeks of drug administration; in the latter, hair loss occurs 2–4 months after starting treatment.

Anagen effluvium is most caused by antineoplastic drugs. Telogen effluvium is seen in association with many drugs, including anticoagulants, retinoids, interferons and antihyperlipidaemic drugs.[34]

2.3 | Skin toxicities to targeted therapy

Targeted therapies interfere in specific molecular pathways that are involved in tumorigenesis, supporting growth, proliferation, metastasis and angiogenesis. By homing in on those pathways rather than broad-based activity, normal tissues could be spared, and adverse events are minimized. However, many of these agents, particularly those interfering with signal transduction (e.g., epidermal growth factor receptor inhibitors, multitargeted tyrosine kinase inhibitors, BRAF inhibitors), are associated with prominent dermatological adverse events that may impact quality of life and due to their intensity can be dose-limiting or lead to therapy discontinuation.[35,36] Acneiform rash is quite common in patients treated with anti-epidermal growth factor receptor agents (50%–100%), this reaction is dose dependent, and appear to be indicative of drug efficacy. Typically, an acneiform rash consisting of pruritic papules and pustules presents within 3 weeks of treatment on skin areas that have sebaceous glands. A similar rash may be seen in patients treated with mTOR inhibitors. The mechanism is thought to be related to follicular hyperkeratosis that causes glands blockage and inflammatory eruption.[35]

Cutaneous adverse effects of MEK inhibitors (trametinib, cobimetinib and binimetinib) are also common and include acneiform eruption, pruritus and xerosis.[37,38]

Other cutaneous toxicities such as changes to the nail bed may be seen, including fragility, paronychia (inflammation of nail folds) and fissures. The hair may also be affected by the use of these agents. Most commonly, hypertrichosis, including growth of the eyelashes and scalp hair, has been reported.[35]

2.4 | Type B

Type B reactions are less common and unpredictable. They are the result of an abnormal response to the drug and usually are not dose dependent. Type B reactions are also known as drug hypersensitivity reactions (DHRs). Depending on their mechanism DHRs can be divided into nonimmune mediated or immunologically mediated.

There are several theories regarding the mechanism of DHRs such as: (i) the hapten hypothesis, where a drug or its metabolites link by a covalent binding to endogenous proteins or peptides forming a hapten-protein complex (IgE or IgG mediate reactions); (ii) the pharmacological interaction, where the drug may directly, reversible binds (noncovalent bond) to HLA or T-cell receptor skipping the antigen-processing pathway in antigen-presenting cells. The interaction between HLA or T-cell receptor is usually selective and may only occur in individuals that carrier a specific HLA allele. (iii) Pseudo allergic, not involving immune mechanisms. DHRs are related to the pharmacological or toxicological profile of the drug and are genetically predetermined. In these cases, drugs can directly trigger a reaction by attaching to receptors or interacting with enzymes of effector cells.[39,40]

Classically, immune-mediated allergy has been divided into 4 main groups using the classical Gell and Coombs system[41–44] (Figure 3).

2.4.1 | Hypersensitivity type I

Hypersensitivity type I is mediated by IgE antibodies which are attached to mast cells and/or basophils with high-affinity Fc

13652125, 2024, 8, Downloaded from https://bpspubs.onlinelibrary.wiley.com/doi/10.1111/bcp.15490, Wiley Online Library on [18/08/2025]. See the Terms and Conditions (https://onlinelibrary.wiley.com/terms-and-conditions) on Wiley Online Library for rules of use; OA articles are governed by the applicable Creative Commons License

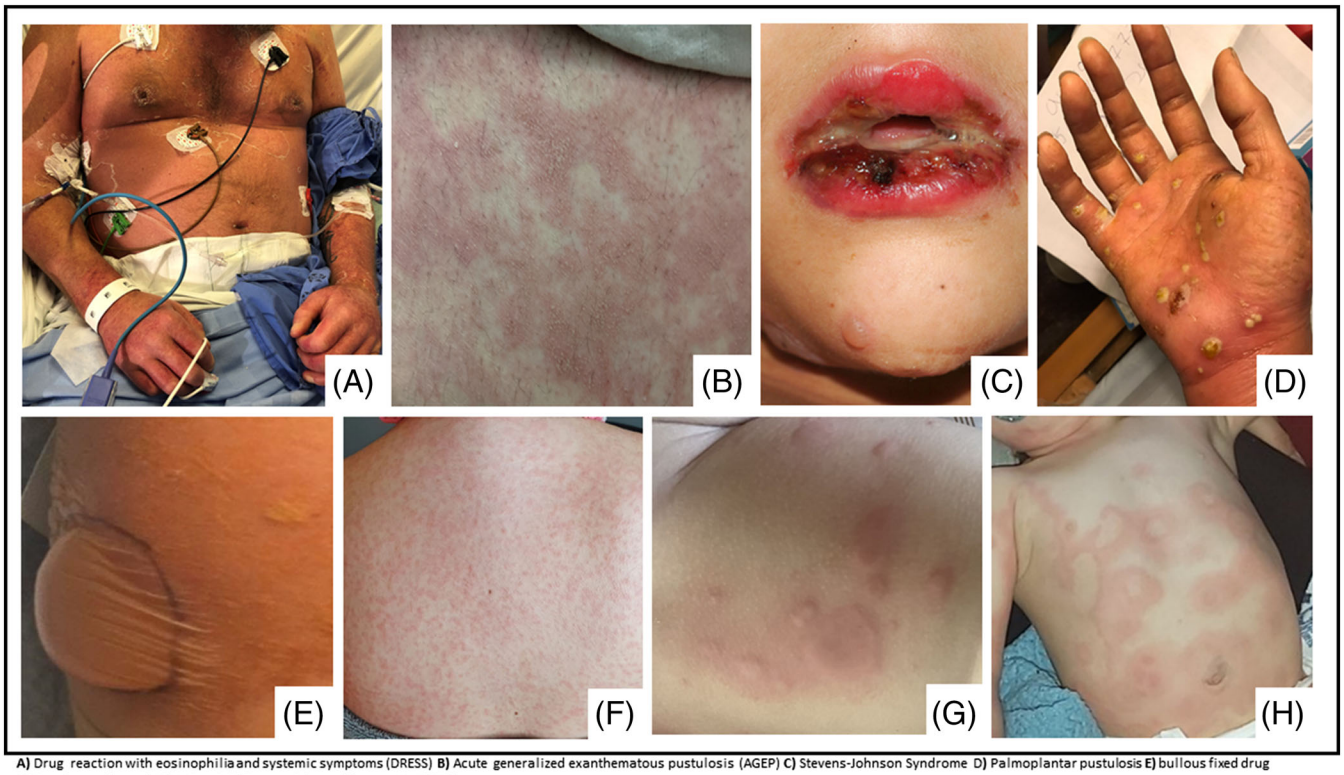

A) Drug reaction with eosinophilia and systemic symptoms (DRESS) **B)** Acute generalized exanthematous pustulosis (AGEP) **C)** Stevens-Johnson Syndrome D) Palmoplantar pustulosis **E)** bullous fixed drug **F)**Maculopapular rash **G)**Urticaria **H)** Serum sickness like reaction(SSLR)

FIGURE 3 Cutaneous adverse drug reactions, type B.

receptors. The patient requires previous sensitization, and it mostly develops immediately after the drug exposure, within the first minutes or hours, that results in the release of histamine and other inflammatory mediators. Key features of these reactions include urticaria, angioedema and anaphylaxis. Recently, a non-IgE-mediated pathway of anaphylaxis has been described. In this new mechanism (IgG-dependent) the effector cells are the macrophages, monocytes and neutrophils instead of the mast cell or basophils and the main mediator is the platelet-activating factor instead of histamine. Drugs associated with this type of reactions include omalizumab, infliximab and dextran among others.[45]

2.4.2 | Hypersensitivity type II

Hypersensitivity type II is usually delayed in onset and is characterized by the abnormal binding of IgG or IgM antibodies to normal host targets, which leads to the complement cascade activation causing inflammation and damage to tissues. (e.g., drug-induced bullous pemphigoid [DIBP]/pemphigus vulgaris).

2.4.3 | Hypersensitivity type III

Hypersensitivity type III is caused by circulating antibody–antigen complexes (IgG bound to foreign antigens), which then precipitate and deposit in several tissues, including blood vessels walls, the skin, kidneys and joints, causing local damage by the activation of the complement cascade. Usually, develops days or weeks after the initial administration of the causative agent but can occur within 12–36 hours in individuals who have been previously sensitized through an antecedent exposure (e.g., SS, leucocytoclastic vasculitis).

2.4.4 | Hypersensitivity type IV

Delayed reactions mediated by a cellular response (T-cells) trigger an inflammatory reaction against exogenous or endogenous antigens. Monocytes, eosinophils and neutrophils may also be involved. Usually appears 1–3 weeks after starting the drug. Type IV reactions are subdivided into 4 groups depending on the T-cell, cytokines and chemokines involved:

a. IVa: macrophage activation (T-helper 1: interferon-γ, tumour necrosis factor [TNF]α,; e.g., contact dermatitis)
b. IVb: eosinophils (T-helper 2: interleukin [IL]-5, IL-4/IL-13,; e.g., maculopapular drug reactions/DRESS)
c. IVc: T CD8 (perforin/granzyme B; e.g., SJS/TEN)
d. IVd: neutrophils (T-cells: CXCL-8, Il-17, granulocyte macrophage colony-stimulating factor; e.g., AGEP)

The 2 most common immune mechanisms associated with the development of cutaneous reactions to drugs are the production of specific

13652125, 2024, 8, Downloaded from https://bpspubs.onlinelibrary.wiley.com/doi/10.1111/bcp.15490, Wiley Online Library on [18/08/2025]. See the Terms and Conditions (https://onlinelibrary.wiley.com/terms-and-conditions) on Wiley Online Library for rules of use; OA articles are governed by the applicable Creative Commons License

IgE antibodies (immediate reactions) and T-cell mediated response (nonimmediate reactions). Peripheral blood mononuclear cells from patients with allergic reactions to drugs show a polarized pattern of cytokine production: Th1 in nonimmediate and Th2 in immediate reactions; additionally, high levels of perforin, granzyme B and Fas-ligand have been related with more severe reactions such as SJSand TEN.[46]

2.4.5 | Nonallergic or nonimmune-mediated reactions

These are known as pseudo-allergic reactions, and are characterized by immediate systemic reactions that are clinically similar to IgE-mediated and sometimes clinically indistinguishable from genuine immunologically mediated allergic reactions (urticaria, angioedema, anaphylaxis); however, they do not involve immunoglobulins, but either a excessive cytokine release, complement activation[47] or direct release of mediators from basophils and mast cells (e.g., red man syndrome, TNF-inhibitor infusion reactions, nonsteroidal anti-inflammatory drug [NSAID] hypersensitivity)[48,49] The latter could be due to the inhibition of specific enzymes (cyclo-oxygenase-1 inhibition), or an off-target occupation of the mast-related G-protein receptor by drugs, such as fluoroquinolones, neuromuscular blocking agents and opiates.[50]

2.5 | Morphology

CADRs could also be classified based on their clinical appearance. A recent classification divides CADRs into 4 main categories: (i) exanthematous; (ii) urticarial; (iii) bullous (blistering); and (iv) pustular. However, some morphological patterns do not fit in any of those categories, so they can be placed in a miscellaneous group. (Table 1) CADRs are further subclassified into simple (benign) or complex (severe).[51] Simple cutaneous drug reactions are mostly limited to the skin and/or mucosae without systemic involvement, while complex conditions are accompanied by systemic signs such as fever, malaise, hypotension, tachycardia, lymphadenopathy, arthritis, respiratory difficulty, hepatic, renal or cardiovascular affectation, etc., which could put at risk the life of the patient (life-threatening). Within the latter group, SJS, TEN, DRESS and AGEP are the most commonly recognized, but other conditions such as SS, drug-induced pemphigus, bullous pemphigoid and linear IgA disease may also present with systemic affectation and might require or prolong patient's hospital admission.[7,52] CADRs patterns that are more common or that have clinical relevance due to their severity are included in this text. However, EM has intentionally not been included in this manuscript because as previously discussed, this condition is mainly triggered by herpes infection or other infectious agents and rarely caused by drugs.[12,53,54]

2.6 | Exanthematous

2.6.1 | Morbiliform or maculopapular drug reactions

This is one of the most common presentations of CADRs, and it is characterized by a diffuse, small, pink to red macules and papules that coalesce into patches and plaques that initially affect the trunk and then rapidly spread to proximal and sometimes distal extremities with a symmetrical distribution.[8] Drugs often associated with morbilliform reactions include antibiotics (most common), antiepileptic and NSAIDs. Drug-induced morbilliform skin rash usually presents within the first weeks of exposure (4–21 d) to a new drug. In some patients, however, cutaneous manifestations developed months or even years after using the same medication without any previous complications.[10,55] The term morbilliform skin rash was initially used to

TABLE 1 Cutaneous adverse drug reactions based in morphology

Exanthematous	Urticaria/urticaria-like or flushing	Pustular	Bullous	Miscellaneous
Morbilliform drug eruption	IgE-mediated urticaria	Drug -induced palmoplantar pustulosis	Bullous fixed drug eruption	Drug-induced SLE
SDRIFE	Urticaria multiforme[a]	AGEP	Erythema multiforme[a]	Alopecia
Drug-induced hypersensitivity syndrome/DRESS	Serum sickness-like reaction	ALEP	Drug-induced bullous pemphigoid	Photosensitivity
Drug-induced erythroderma	Serum sickness	Drug-induced subcorneal pustular dermatosis	Drug-induced pemphigus	Vasculitis
Serum sickness	NSAIDs hypersensitivity (urticaria/angioedema)		Drug-induced linear IgA bullous dermatosis	
Contact dermatitis	Red man syndrome		Drug-induced dermatitis herpetiformis	
Leukocytoclastic vasculitis (purpuric)	Infusion reaction		SJS/TEN	
			Bullous DRESS	
			Contact dermatitis	

AGEP, acute generalized exanthematous pustulosis; ALEP, acute localized exanthematous pustulosis; DRESS, drug reaction with eosinophilia and systemic symptoms; NSAID, nonsteroidal anti-inflammatory drug; SJS/TEN, Stevens–Johnson syndrome and toxic epidermal necrolysis spectrum; SDRIF, symmetric drug-related intertriginous and flexural erythema; SLE, systemic lupus erythematosus.

[a]These conditions are mostly associated with infectious agents.

13652125, 2024, 8, Downloaded from https://bpspubs.onlinelibrary.wiley.com/doi/10.1111/bcp.15490, Wiley Online Library on [18/08/2025]. See the Terms and Conditions (https://onlinelibrary.wiley.com/terms-and-conditions) on Wiley Online Library for rules of use; OA articles are governed by the applicable Creative Commons License

describe the cutaneous manifestations of the measles infection and now is widely used to describe skin eruptions with similar morphology[8] Morbilliform drug reactions do not present with blistering or sloughing of the skin, and enanthem seldom occurs.[56,57] Other accompanying features include low-grade fever and itchiness of variable intensity, although skin rash is reported to be more tender or painful. Usually, the skin rash picks after drug withdrawal and subsides after 1–2 weeks without any sequelae, although sometimes it may present with postinflammatory desquamation.[56]

2.6.2 | Symmetric drug-related intertriginous and flexural erythema

Symmetric drug-related intertriginous and flexural erythema (SDRIFE) is also known as baboon syndrome, and is characterized by an erythematous and pruritic eruption mostly localized to flexural skin surfaces such as gluteal and/or inguinal areas. These lesions are well demarcated and can be associated with eczema, scaling or desquamation of affected areas.[58] The most common drugs associated with this condition are penicillin and cephalosporins; however, many other drugs could also trigger it, including clindamycin, erythromycin, nystatin, fluconazole, metronidazole and valacyclovir. The precise pathogenic mechanism underlying SDRIFE is still unclear, however, it is thought to involve a type IV delayed-hypersensitivity immune response supported by immunohistochemical evidence of CD4 + T cell infiltration. SDRIFE is a self-limited condition without systemic involvement.[59,60]

2.6.3 | DRESS

DRESS, also known as drug-induced hypersensitivity syndrome (DIHS), is considered a SCAR and is thought to be caused by drugs or their metabolites. The average time to develop the symptoms after the drug exposure is between 3 and 9 weeks.[61,62] The drugs most frequently associated with DRESS/DIHS include antimicrobial sulphonamides, aromatic amine anticonvulsants, β-lactam antibiotics, allopurinol, NSAIDs and antiretrovirals. Additionally, coincidental viral reactivation of human herpesvirus-6, other viruses in the human herpesvirus family, CMV and EBV, and an ethnic predisposition with specific human leucocyte antigen (HLA-A*31:01, HLADRB1*01:01, HLA-B*35:05) alleles seem to play an import role in the pathogenesis of this condition.[42,63–65] Clinically, DRESS/DIHS presents with a fever >38–40°C, which is followed by a pruritic exanthema that is often described as diffuse, erythematous macular or maculopapular, which could turn violaceus. Skin rash is often accompanied by facial oedema. A less common presentation includes other cutaneous morphologies such as pustules, blisters, lichenoid, eczematous and exfoliative lesions[66] Patients usually presents with palpable lymphadenopathy and internal organ injury that presents with varying degrees of severity.[61] The organs most commonly affected are the liver, followed by the kidneys and lungs, while the heart, gastrointestinal tract and central nervous system are less frequently involved.[42] Laboratory abnormalities include leucocytosis with peripheral eosinophilia, atypical lymphocytes, thrombocytopenia and abnormal liver and renal function tests.[67] Although eosinophilia is a hallmark of DRESS/DIHS, this feature could be absent or delayed after the elevation of liver enzymes return to normal. Conversely, mucosal involvement is occasionally present, but that does not necessarily exclude the diagnosis of DRESS/DIHS. To emphasize when it is present, the affectation is much less severe and haemorrhagic than SJS/TEN.[68] Patients recovering from DRESS/DIHS have a high risk of developing autoimmune condition such as Grave's disease, Hashimoto's thyroiditis, type I diabetes and haemolytic anaemia, so long-term monitoring is recommended.[69]

2.7 | Urticaria and urticaria-like reactions

2.7.1 | Urticaria

Urticaria is a condition characterized by the development of wheals/hives that may affect any part of the body (face, trunk, extremities) and may or may not be accompanied by angioedema (swelling of the deep layers of the skin). Three important features define hives: a central swelling surrounded by erythema, an itching or burning sensation, and fleeting nature. Individual lesions usually resolve within 30 minutes to 24 hours leaving no mark or residual hyperpigmentation.[70] Urticaria is caused by the release of inflammatory mediators form mast cells and basophils either by immune mechanisms such as type I hypersensitivity reaction (e.g., IgE-mediated) and nonimmune mechanisms (direct mastocyte degranulation by NSAIDs).[8] Hives or urticarial lesions could be initially solitary or multiple; their size varies from a few millimetres to several centimetres. Morphology may also vary as small pink papules, macules or large red oedematous wheals. Sometimes they present with annular or pseudo annular (partial rings) or polycyclic patterns. Their evolution is dynamic and, as they develop, they can fade and reform in different body areas. The most common drugs associated with this presentation include NSAIDs, sulfonamides, phenytoin, morphine, codeine, penicillin and cephalosporins. Oral antihistamines are usually helpful in reducing the associated pruritus and appearance of lesions.[56] Anaphylaxis is an acute life-threatening reaction characterized multiorgan involvement (hypotension, bronchospasm or gastrointestinal symptoms) and is usually accompanied by urticaria/angioedema. Prompt recognition of the severe symptoms and administration of epinephrine are key to avoid deadly consequences.[71]

2.7.2 | Serum sickness

SS is a hypersensitivity reaction mediated by immune complexes (type III hypersensitivity reaction) and is characterized by the development of fever, skin rash and joint involvement. This condition was initially described in 1906 in patients that received antiserum from a nonhuman source. The symptoms usually present 1 or 2 weeks after the

13652125, 2024, 8, Downloaded from https://bpspubs.onlinelibrary.wiley.com/doi/10.1111/bcp.15490, Wiley Online Library on [18/08/2025]. See the Terms and Conditions (https://onlinelibrary.wiley.com/terms-and-conditions) on Wiley Online Library for rules of use; OA articles are governed by the applicable Creative Commons License

exposure to the offending agent (rabies vaccine, immune-modulating agents and antivenoms).[72,73] The rash in SS has been described as urticarial. However, it may also present as maculopapular or vasculitic eruption. At the same time, joint involvement is mostly characterized by arthralgias of hands, feet, ankles, knees and shoulders, but true arthritis could also be present. Additional symptoms could include lymphadenopathy, headache, neuropathy or vasculitis. The laboratory tests can show low levels of complement (CH50, C3–4), elevation of serum creatinine and leucopoenia or mild leucocytosis. Fortunately, SS is a self-limited condition that usually resolves several weeks after the discontinuation of the offending agent.[74,75]

2.7.3 | Serum sickness-like reaction

SS-like reaction (SSLR) is an immunological condition characterized by the sudden development of skin rash and joint inflammation with or without fever, usually preceded by exposure to a drug. Its name was given to the clinical similarities with the classic SS, but now is considered that these are 2 different entities.[76] The skin rash is described as urticaria-like and is characterized by erythematous papules and macules of different sizes that evolve into annular lesions with/without purplish discoloration. However, unlike classic SS reaction, skin lesions in SSLR are not true urticaria as they are not transient but remain in the same area for several days (fixed). In addition, patients may present with eye and lip oedema but do not present with respiratory difficulties or anaphylaxis. Skin rash is accompanied by severe inflammation and pain of acral joints (mostly hands/feet) but other joints could also be affected.[77] SSLR is a self-resolving condition with no systemic organ involvement, but it is often associated with severe malaise, irritability and fever.[8] Although SSLR pathophysiology remains unclear, it is essential to differentiate it from classic SS as the former is not mediated by antigen–antibody complex formation; instead, it has been hypothesized that the trigger drugs or their metabolites can induce a type IV hypersensitivity reaction.[78] Even though some infectious agents have been reported to trigger SSLR, antibiotics such as β-lactams (amoxicillin and cephalosporins) are the most common drugs associated with this condition.[79] Evidence has suggested that SSLR may recur if patients are re-exposed to the same medication; however, the precise rate of recurrence has not been properly established.[76]

2.8 | Bullous

2.8.1 | Fixed drug eruption bullous type

Fixed drug eruption (FDE) is a common CADR characterized by well-demarcated erythematous patches or plaques that may present with overlying blistering. Medications associated with FDE are NSAIDs, paracetamol, antihistamines and antimicrobials.[80] Recreational use of codeine in adolescents is a well-documented cause of FDE.[56] The time of presentation after the drug exposure varies from a couple of days to several weeks.[81] As a hallmark of this condition, patients develop recurrence of the skin lesions in areas previously affected when they are re-exposed to the same drug. After the withdrawal of the drug, the lesions will fade but leave behind areas of residual hyperpigmentation. The morphology of FDE can vary from urticaria-like to bullous. The patient may present solitary or multiple lesions, which, when generalized, may mimic TEN.[82] Upper extremities and lips are the most frequent areas affected, but it can affect any part of the body, including genitals and other mucosae.[83]

2.8.2 | Drug-induced boullus pemphigoid

DIBP is an autoimmune disease characterized by the development of blisters (type II hypersensitivity reaction). Although bullous pemphigoid is often idiopathic, in some cases, drugs have been implicated in the pathogenesis of the disease. Unlike idiopathic bullous pemphigoid, which usually presents in older adults, DIBP presents at younger ages. The clinical presentation is characterized by tense bullae overlying erythematous or urticarial plaques; however, they may also present on normal-appearing skin.[84] The most common culprits associated with DIBP include furosemide, penicillamine, captopril, NSAIDs and dipeptidyl peptidase-4 inhibitors or gliptins.[85] The precise mechanisms by which drugs trigger DIBP are still unknown but, similarly to other CADRs, it has been suggested that specific HLA alleles could contribute to the susceptibility to develop this condition. The course of DIBP could diverge from self-limited after the withdrawal of the drug or could persist chronic after removing the offending drug requiring prolonged treatment.[86]

2.8.3 | Stevens-Johnson syndrome and toxical epidermal necrolysis

These are uncommon but the most feared CADRs due to the high morbidity, mortality and long-term sequelae associated with these conditions. For years, controversy regarding its name, classification, types, diagnostic criteria and aetiology has resulted in overdiagnosis and a lack of consensus about its proper treatment.[13] Current classification considers SJS and TEN as the same condition but located in a different spectrum of severity and is based on the percentage of skin detachment. SJS affects <10% of the body surface area (BSA), while TEN represents a more severe form involving >30% of BSA. SJS/TEN overlap is considered when skin detachment or detachable skin affects between 10 and 30% of BSA.[53] SJS/TEN usually develops between 7 and 21 days after the initial exposure to the drug and may present with prodromic nonspecific symptoms (fever, respiratory symptoms, malaise) for a couple of days before the appearance of the mucocutaneous lesions. Skin lesions may present as painful, erythematous, targetoid, dusky or purpuric amorphous macules and patches, which rapidly progress (within 12 h) to flaccid blisters and haemorrhagic erosions. Nikolsky's sign is present on the affected skin or adjacent to blisters. Lesions usually start on the face and/or thorax and then

13652125, 2024, 8, Downloaded from https://bpspubs.onlinelibrary.wiley.com/doi/10.1111/bcp.15490, Wiley Online Library on [18/08/2025]. See the Terms and Conditions (https://onlinelibrary.wiley.com/terms-and-conditions) on Wiley Online Library for rules of use; OA articles are governed by the applicable Creative Commons License

spread centrifugally (symmetrically) to the rest of the body. Mucosal involvement (oral, conjunctive, genital, anal) may precede cutaneous lesions being oral and ocular mucosae are the most frequently and severely affected. In addition to the cutaneous manifestations, patients are severely ill, often presenting internal organ affectation (liver, kidneys, lungs, gastrointestinal tract, bone marrow and joints). Patients have a high risk of developing skin or systemic infections leading to sepsis, which is the most common and severe complication of SJS/TEN. Blindness, renal damage, pigmentary changes, scarring and mucosal strictures, and psychiatric conditions are often reported as long-term complications.[52,87,88] Recently, a new classification of SJS and TEN has been proposed where drug-induced SJS/TEN will be renamed as drug-induced epidermal necrolysis, while those triggered by infections (e.g., *Mycoplasma pneumoniae* and viruses) will be classified as reactive infectious mucocutaneous eruption.[89]

2.9 | Pustular

2.9.1 | Drug-induced palmoplantar pustulosis

This is an uncommon inflammatory disease that affects mainly palms and/or soles and is characterized by the development of sterile pustules. The exact cause of palmoplantar pustulosis (PPP) is unknown, and there is still debate about whether PPP is a variant of psoriasis or a distinct condition. Most common triggers include smoking, inflammatory diseases, respiratory infection and some medications such as Janus kinase inhibitors and anti-TNF agents.[90,91] Clinical features include the abrupt eruption of sterile pustules on an erythematous-squamous background. It may also be associated with nail changes, hyperkeratosis, erythema, scaling and fissuring, which is associated with severe pain and discomfort.[92,93] The pathophysiology of PPP remains unclear, but several studies have shown that the IL-17 and IL-36 pathways may be involved in its pathogenesis.[94]

2.9.2 | Acute generalized exathemaous pustulosis

This condition presents as a generalized small nonfollicular sterile pustular skin rash with an erythematous base which is accompanied by fever and occasionally with systemic symptoms. Initially, the rash presents as oedematous erythema with an intertriginous predilection (armpits, neck and groin), followed by the appearance of hundreds to thousands of small (pin size), coalescing, sterile pustules with an erythematous base that rapidly spread to trunk and limbs. Mucosal involvement occurs in approximately 20% of oral nonerosive lesions, while systemic involvement is rare, especially in children.[51,95] Most of the cases (up to 90%) are secondary to drug exposure; however bacterial, viral or parasitic infections could also trigger this condition.[96] Although rare, some severe cases of AGEP may simulate other severe drug hypersensitive syndromes such as SJS/TEN.[97] Overall, AGEP is a rare condition with an estimated incidence of 1–5 patients per million patients while paediatric patients represent only a minor percentage of affected patients.[48] The drugs most often associated with AGEP include ampicillin/amoxicillin, pristinamycin, quinolones, sulfonamides, terbinafine, diltiazem, ketoconazole and fluconazole[95] Although the precise physiopathology of AGEP remains unclear, it is considered that AGEP is a type IV hypersensitivity.[96] Resolution of skin rash is between 4 to 10 days followed by pin-point desquamation over the affected areas, including palms and soles. Prognosis is overall good, with a mortality rate of 5% when multiple organ dysfunction is present.[98,99]

2.9.3 | Acute localized exanthematous pustulosis

This is the localized form of AGEP and is characterized by multiple nonfollicular sterile pustules overlying an erythematous background that develops acutely after drug exposure. Acute localized exanthematous pustulosis usually affects the face, neck or chest. The lesions arise quickly (hours) and resolve similarly in only a couple of days, even without treatment. It is often accompanied by fever and neutrophilic leucocytosis but does not present internal organ involvement.[100]

2.10 | Miscellaneous

2.10.1 | Drug-induced lupus

Is the presence of systemic lupus erythematosus (SLE) manifestations occurring after the exposure to specific medications. Drug most commonly associated with drug-induced lupus include hydralazine, procainamide, minocycline, isoniazid, quinidine and methyldopa Specific classification criteria for drug-induced lupus have not been published, and no published data address differences between adult and paediatric drug-induced lupus.[101] Thus drug-induced lupus is presumed not to differ across the age spectrum as affects males and females equally and is unlikely to cause significant renal or CNS disease. Hepatic involvement in drug-induced lupus is common. Laboratory abnormalities can include circulating anti-histone antibodies, although these antibodies can also be present in SLE unassociated with drug exposure. Anti-dsDNA antibodies are less likely to occur in drug-induced lupus. The presentation of drug-induced lupus varies from systemic involvement (drug-induced SLE [DI-SLE]) to disease limited to the skin (drug-induced subacute cutaneous lupus [DI-SCLE]). Clinical features of DI-SLE differ from those that occur in SLE. Notably, DI-SLE is characterized by the presence of fever, arthralgia/arthritis, myalgia and serositis; internal organ involvement, such as lupus nephritis and central nervous system disease, is rare. Classic cutaneous lesions of SLE, such as malar rash and discoid rash, are rare in DI-SLE. In contrast, DI-SCLE consists of annular-polycyclic or psoriasiform lesions in a photosensitive distribution, often accompanied by anti-SSA antibodies.[102] ANAs are universally present and anti-histone antibodies are detectable in 75% of patients with DI-SLE. Symptoms should improve within days to weeks of drug discontinuation.[103]

13652125, 2024, 8, Downloaded from https://bpspubs.onlinelibrary.wiley.com/doi/10.1111/bcp.15490, Wiley Online Library on [18/08/2025]. See the Terms and Conditions (https://onlinelibrary.wiley.com/terms-and-conditions) on Wiley Online Library for rules of use; OA articles are governed by the applicable Creative Commons License

2.10.2 | Drug-induced vasculitis

Drug-induced vasculitis is characterized by inflammation of the blood vessels that usually attacks the skin and the subcutaneous tissue. Sometimes, it also affects kidneys and lungs.[104] Clinical manifestations vary from small vessel hypersensitivity vasculitis and leucocytoclastic vasculitis to systemic forms that mimic more severe forms of vasculitis such as Wegener's granulomatosis, polyarteritis nodosa and Churg–Strauss syndrome.[105] Leucocytoclastic vasculitis is the most common form of cutaneous vasculitis (30%) and usually presents as palpable purpuric or petechial skin rash usually affecting lower extremities. It could also be accompanied by skin ulceration or oedema. In severe cases it may present with systemic involvement such as arthralgias, gastrointestinal symptoms or nephropathy,[106] Most common associated drugs include penicillin, sulfonamides, quinolones, allopurinol, propylthiouracil, anti-TNFα agents, NSAIDs and hydralazine. Discontinuation of the culprit drug often results in the resolution of the symptoms.[107]

2.10.3 | Drug-induced photosensitivity

This is a reaction induced by the interaction between sun exposure and certain medications. There are 2 main mechanisms of this reaction: (i) photoallergic and (ii) phototoxic.[108] Overall, they are characterized by affecting sun-exposed areas, although in some photoallergic reactions the lesions can spread over the entire skin surface. Drugs mostly associated with these conditions include thiazide diuretics, tetracyclines, NSAIDs, simvastatin, itraconazole, fluoroquinolones, escitalopram, isotretinoin, griseofulvin, cefotaxime, antifungals, antimalarials, β-blockers and TNF inhibitors.[109] Photoallergic reactions are mediated by T cells or antibodies in response to a photosensitizing agent. The drug or its metabolites bind (photobinding) to the protein carrier forming a photoantigen. Photoallergic reactions require an incubation period for the immunological memory, so they present after several days. They need a small amount of drug to induce a photoallergic reaction and can present cross-reactivity with drugs with similar molecular structure. Dermatological phenotypes associated with photoallergy include eczematous eruption (acute phase) or lichenoid reaction (delayed). By contrast, phototoxic reactions are a result of direct cellular damage by photoactivated compounds. They are more common than photoallergic reactions and develop within minutes or few hours after the sun exposure. In addition, they are dose-dependent and require a high drug concentration to develop. Unlike photoallergic reactions there is no cross-reactivity between structurally related drugs. Phototoxic reactions are usually characterized by erythema like an *exaggerated sunburn*. Other patterns include skin hyperpigmentation, onycholysis, pseudoporphyria (bullous lesions) and telangiectasis.[110–112]

3 | APPROACH TO CADRS

A general approach to CADRs is shown in Figure 4. The first step after suspecting a CADR is to initiate the withdrawal of medication. This should be done if the offending medication can be replaced with another drug, or if the skin reaction is severe enough to require the rapid cessation of suspect drugs (evaluation of the risk/benefit ratio).[113] Polypharmacy, or the use of multiple medications, can make the determination of the offending agent even more difficult.[113] The search for bibliographic information and the pharmacovigilance statement is essential.

The approach of any CADR starts with a good history, which should include a recording of all prescription and nonprescription drugs taken within the last month, including dates of administration and dosage. The temporal relationship between drug intake and the onset of clinical symptoms is critical as well as the evolution after the discontinuation of the drug. Previous exposures to the same drug (sensitization) and history of another adverse drug reaction are also key to determine drug causality.[114]

The physical examination may provide further information to support drug hypersensitivity. An essential step is the detailed evaluation of signs and symptoms especially in any immediate generalized reaction because this could present as a severe or life-threatening drug reaction. Warning signs of impending cardiovascular collapse include generalized urticaria, laryngeal or upper airway oedema, wheezing and hypotension. In delayed reactions, signs suggestive of serious or severe condition include the presence of fever, mucous membrane lesions, lymphadenopathy, joint tenderness and swelling, internal organ involvement (e.g., liver, kidneys), or an abnormal pulmonary examination.

A very important step in the approach of any CADR is a detailed skin examination. This should include location or pattern of distribution of the skin rash, identification of the morphology (e.g., papular, macules, blisters, pustules, scaling) and configuration of skin lesion (e.g., annular, arcuate, confluent, linear) as well as the accompanying symptoms (itchiness, pain, burning sensation). Proper and accurate distinction between the various types of skin lesions may provide substantial clues to the possible mechanism and type of drug reaction.[114]

In some cases, scoring algorithms for specific CADRs (e.g., RegiSCAR score for DRESS) and drug causality tools (e.g., Naranjo score) could be useful during the assessment of patients with a suspected ADR. They evaluate clinical, laboratory and histological parameters or the likelihood between drug exposure and the occurrence of the ADR. Some examples are shown in Table 2.[98,115–120]

3.1 | Laboratory and allergy testing

In addition to an excellent clinical approach, laboratory, histology and specific drug allergy testing could support the suspected diagnosis. The selection of diagnostics tools will depend on the type of the reaction and its potential mechanisms. Testing could be performed in vivo (within a living organism) or in vitro (outside a living organism). Table 3)

13652125, 2024, 8, Downloaded from https://bpspubs.onlinelibrary.wiley.com/doi/10.1111/bcp.15490, Wiley Online Library on [18/08/2025]. See the Terms and Conditions (https://onlinelibrary.wiley.com/terms-and-conditions) on Wiley Online Library for rules of use; OA articles are governed by the applicable Creative Commons License

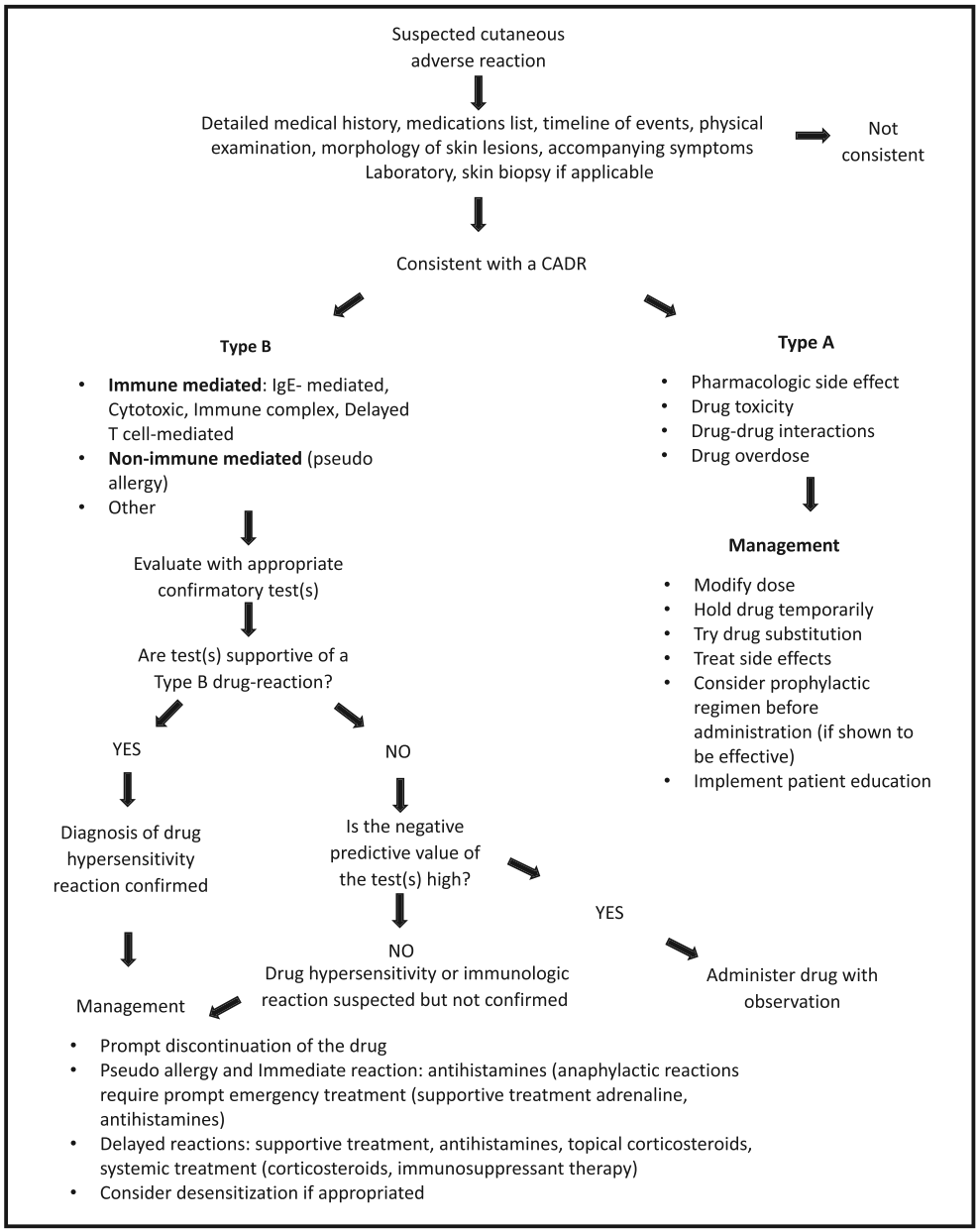

FIGURE 4 Evaluation and management of cutaneous adverse drug reactions (CADRs)

Adapted from Riedl MA, Casillas AM. Adverse drug reactions: types and treatment options. Am Fam Physician. 2003 Nov 1;68(9):1781-90.

3.1.1 | In vivo testing

It is recommended to perform these tests several weeks or months after the drug reaction has entirely resolved to avoid potential flares or reactivation of the reaction. Treatment with antihistamines and/or steroids could interfere with the results, so these drugs should be avoided or stopped before the test.[121]

Drug provocation test (challenge)

This test is defined as the controlled administration of a drug to diagnose a DHR and can be used in nonimmune and immune-mediated drug reactions. Currently, this test is considered the gold standard to determine the causality in any drug reaction; however, due to the risk of recurrences, especially for severe drug reactions, its use is limited. Thus, only well-trained professionals should conduct this testing to exclude hypersensitivity in nonsuggestive histories or patients with suggestive histories of drug hypersensitivity but with mild or nonspecific symptoms. In some cases, it also could be performed to establish a firm diagnosis or to exclude cross-reactivity of related drugs in proven hypersensitivity with negative, nonconclusive or nonavailable allergology test (e.g., NSAIDs hypersensitivity). A mindful assessment of the risks and benefits should be done before a drug provocation is performed.[122,123]

Dermatological tests (skin tests)

These include skin prick test, intradermal test and patch test. Reading for prick and intradermal skin testing to diagnose IgE-mediated immediate type hypersensitivity is usually done after 15–20 minutes, while patch tests require more time (24–96 h). The

13652125, 2024, 8, Downloaded from https://bpspubs.onlinelibrary.wiley.com/doi/10.1111/bcp.15490, Wiley Online Library on [18/08/2025]. See the Terms and Conditions (https://onlinelibrary.wiley.com/terms-and-conditions) on Wiley Online Library for rules of use; OA articles are governed by the applicable Creative Commons License

TABLE 2 Example of diagnostic scoring algorithms and drug causality tools for CADRs

Disease likelihood	**1.- AGEP validation score (EuroSCAR group)** Based on clinical. Laboratory and histological features • Score −10 to 0: No AGEP; score 1–4: Probable; score 5–7: Definite **2.- RegiSCAR score (DRESS)** Based on clinical, laboratory and histological features • Score < 2: No case; score 2–3: Possible; score 4–5: Probable; score > 5: Definite **3.- J-SCAR (DRESS)** Bases on clinical and laboratory features enlisted from 1 to 7 • The diagnosis is confirmed by the presence of all 7 criteria (typical) or from 1–5 (atypical)
Drug causality	**1.- Naranjo score** The ADR probability scale consists of 10 questions. Different point values (−1, 0, +1 or +2) are assigned to each answer (from −4 to 13) • Score 9 or higher: definite; score 5–8: probable; score 1–4: possible if 1–4; ≤0: doubtful **2.- Liverpool causality assessment tool** Flow diagram conformed by sequential questions designed to determine the likelihood of drug causality **3. ALDEN score (SJS/TEN)** Based on 6 parameters, score range from −12 to 10. Score <0: very unlikely; score 0–1: unlikely; score 2–3: possible; score 4–5: probable; score ≥6: Very probable

AGEP, acute generalized exanthematous pustulosis; DRESS, Drug reaction with eosinophilia and systemic symptoms; J-SCAR, Japanese Consensus Group; RegiSCAR, European registry of severe cutaneous adverse reactions.

TABLE 3 Drug hypersensitivity testing for cutaneous adverse drug reactions

Drug-induced skin disease type		In vivo testing	In vitro testing	Additional testing
Immediate reaction				
IgE mediated (Urticaria, angioedema, anaphylaxis)		Skin test (prick test) Oral challenge[a]	BAT (not widely available) RAST/ImmunoCAP	Tryptase
Non-IgE mediated urticaria and angioedema (NSAIDs hypersensitivity)		Oral challenge[a]	Not available	Not available
Delayed reaction				
Type II hypersensitivity reaction (drug-induced bullous pemphigus/pemphigoid)		Oral challenge[a]	Not available	Skin biopsy (H&E, immunofluorescence) Serum (indirect immunofluorescence)
Type III hypersensitivity reaction (serum sickness reaction)		No recommended	LTA (not widely available)	Skin biopsy
Type IV hypersensitivity reaction	• Maculopapular rash	Oral challenge[a] IDT	LTA, LTT (not widely available)	Skin biopsy
	• Contact dermatitis	Patch test	Not available	Skin biopsy
	• DRESS	IDT	LTA, LTT, ELISpot (not widely available)	Skin biopsy
	• AGEP	Patch test IDT	LTA, LTT, ELISpot (not widely available)	Skin biopsy
	• SJS/TEN	Not recommended	LTA, LTT, ELISpot (not widely available)	Skin biopsy

AGEP, acute generalized exanthematous pustulosis; BAT, basophil activation testing; DRESS, drug reaction with eosinophilia and systemic symptoms; ELISpot, enzyme-linked ImmunoSpot; H&E, hematoxylin and eosine; IDT, intradermal testing; IgE, immunoglobulin E; LTA, lymphocyte toxicity assay; LTT, lymphocyte transformation test; NSAID, nonsteroidal anti-inflammatory drug; RAST, radioallergosorbent test.
[a]Not indicated when there is history of severe reaction or anaphylaxis.

results are obtained by measuring the diameter of the wheal and/or erythema on the application site. Negative or positive controls are used to compare results. The sensitivity of these tests varies depending on the drug, its concentration and the type of reaction.[124–126] The prick test consists of pricking the skin with a sterile lancet or similar device through a drop of solution containing

13652125, 2024, 8, Downloaded from https://bpspubs.onlinelibrary.wiley.com/doi/10.1111/bcp.15490, Wiley Online Library on [18/08/2025]. See the Terms and Conditions (https://onlinelibrary.wiley.com/terms-and-conditions) on Wiley Online Library for rules of use; OA articles are governed by the applicable Creative Commons License

a specific allergen that penetrates the epidermodermal junction zone. This is the most practical and available test for immediate (IgE-mediated) CADRs. The intradermal test is done by injecting 0.02–0.05 mL of allergen (nonirritating concentrations) intradermally, leading to a small bleb. This test is limited to sterile liquid drug formulations and could be used to diagnose immediate or delayed DHRs. A patch test is performed by applying a specific concentration of the antigen in small plates that are fixed on the back of the patient for a couple to several days. This test is mainly used for the diagnosis of contact dermatitis, but its use has been expanded to other nonimmediate CADRs (e.g., maculopapular rash, DRESS, AGEP and SJS/TEN).[97,127]

3.1.2 | In vitro testing

These tests can help to clarify a diagnosis and confirm causality and do not represent a risk of potential harm by reactivation of the reactions. However, they can be more expensive and not all are widely available.[128]

Skin biopsy

Histopathological patterns found in CADRs may be not entirely specific, but they can provide some clues and aid in reaching a specific diagnosis. Although skin biopsy has a high value in the assessment of these conditions, it may not definitely exclude alternative causes or other entities.[129,130]

Specific IgE testing

These tests include radioallergosorbent test (RAST) and ImmunoCAP. They provide an objective measurement of the circulating drug specific IgE antibodies. This test is indicated for diagnosing immediate IgE-mediated reactions induced by β-lactam drugs; however, the usefulness of these tests is controversial and not well determined. Their sensitivity could range from 19 to 75% and the specificity could be as high as 67–100%[131,132] Positive predictive values are lower than negative predictive values.[133]

Lymphocyte transformation test

This test measures the proliferation of T cells in response to a specific drug in vitro and is based on the activation and expansion of the drug-specific memory T cells following coincubation of the patient's peripheral mononuclear cells with the suspected drug in vitro. This test can be applied to different drugs and immune reactions. In patients with DRESS and other delayed hypersensitivity reactions, its sensitivity and specificity have been demonstrated to be as high as 73% and 95%, respectively.[134–136]

Lymphocyte toxicity assay

Similar to the lymphocyte transformation test, the lymphocyte toxicity assay (LTA) uses peripheral mononuclear cells to assess the causality of a specific drug in T-cell mediated ADRs. However, LTA mainly evaluates the patient's T-cell viability when exposed to different concentrations of the trigger drug compared with T-cells of a healthy control. Its sensitivity, specificity, NPV and PPV seem to vary according to the drug involved in the reaction. Still, LTA has proven to be a handy diagnostic tool for delayed hypersensitivity reactions to many drug classes, including aromatic anticonvulsants, sulfonamides and β-lactam antibiotics.[137,138]

Basophil activation test

This test establishes allergen-induced basophil activation using flow cytometry. It has been validated in IgE-mediated allergies, including life-threatening anaphylaxis. Its sensitivity and specificity depend on the drug testing. For the β-lactam drugs, basophil activation test sensitivity and specificity could reach 78–97%, respectively.[131,139]

Enzyme-linked ImmunoSpot assay

This test detects locally secreted cytokine molecules, such as interferon-γ, using antibody-coated plates offering both a qualitative but also a quantitative specific protein measurement, measuring cytokine production on a per-cell basis[140] It is used to determine drug causality in severe delayed DHRs such as SJS/TEN, DRESS and AGEP. A recent study showed that enzyme-linked ImmunoSpot performance depends on the type of drug tested or the DHR phenotype and suggested that its sensitivity increases if performed within 30 days after onset of DHR or during the acute phase of DHR. The sensitivity and specificity of this test varies but overall, the sensitivity is reported to be around 52% while specificity could reach 86% to up to 100%[115,141] Similar to lymphocyte transformation test and LTA, enzyme-linked ImmunoSpot is not available for routine diagnostic use in most centres.

Finally, in addition to the aforementioned specialized tests, several laboratory tests are valuable tools to support a potential diagnosis and monitor disease progression and treatment response, although negative or normal results do not rule out a CADR. These include among others: complete blood count and differential, liver function tests, inflammatory markers, complement, tryptase and creatinine.[97]

4 | TREATMENT

A detailed description of treatment options for CADRs is outside of the objectives of this manuscript; however, in general the management of these conditions will start by discontinuing the suspected trigger drug. Supportive care will depend on the severity of the reactions. For mild to moderate reactions, antihistamines, NSAIDs and topical corticosteroids could be required, while for severe reactions, systemic steroids (e.g., 0.5–1 mg/kg/d of prednisone) or other immunosuppressive agents (cyclosporine, TNF inhibitors or other biological therapy) should be carefully evaluated as their efficacy is still controversial.[113,142]

Hospitalization is indicated when CADRs present certain signs of severity including cutaneous (skin surface >60%, erythema confluence, facial oedema, skin pain, palpable purpura, skin necrosis, bullae or epidermal detachment, positive Nikolski's sign, mucosal erosions, urticaria, and/or tongue oedema), general (high fever,

13652125, 2024, 8, Downloaded from https://bpspubs.onlinelibrary.wiley.com/doi/10.1111/bcp.15490, Wiley Online Library on [18/08/2025]. See the Terms and Conditions (https://onlinelibrary.wiley.com/terms-and-conditions) on Wiley Online Library for rules of use; OA articles are governed by the applicable Creative Commons License

lymphadenopathy, arthralgia or arthritis, expiratory dyspnoea or difficulty breathing, cardiovascular affectation or hypotension), and biological (eosinophilia >1000/μL, lymphocytosis with atypical lymphocytes, liver function, kidney or heart abnormalities).[113]

5 | CONCLUSIONS

CADRs are common conditions. Their severity varies from mild or self-resolving to life-threatening conditions that could put in risk the life of the patients or affect their quality of life. The diagnosis of CADRs could be challenging due to the wide spectrum of clinical patterns. The approach to a proper diagnosis should be based on different elements including morphology of the skin rash, associated symptoms, the timing of the drug exposure, in vivo or in vitro laboratory (when available) and histology. Prompt identification and discontinuation of the trigger drug are essential to limit progression of the disease. Treatment should be based on the severity of the skin and systemic affectation.

ACKNOWLEDGEMENTS

We thank Dr Alejandro Lazo-Langner who provided insight and expertise that greatly improved the manuscript. The author(s) received no financial support for the research, authorship and/or publication of this manuscript.

COMPETING INTERESTS

All authors declare that they have no conflicts of interest to disclose.

ORCID

Blanca R. Del Pozzo-Magaña https://orcid.org/0000-0002-8597-5485

REFERENCES

1. Law RM, Law DTS. Dermatologic Drug Reactions and Common Skin Conditions. In: DiPiro JT, Talbert RL, Yee GC, Matzke GR, Wells BG, Posey LM, eds. *Pharmacotherapy: A Pathophysiologic Approach, 10e*. New York, NY: McGraw-Hill Education; 2017.
2. Hacker M. Chapter 13 - Adverse Drug Reactions. In: Hacker M, Messer W, Bachmann K, eds. *Pharmacology*. San Diego: Academic Press; 2009:327-352 10.1016/B978-0-12-369521-5.00013-0.
3. Hina A 2nd, Masood S, Jamil S, Tabassum S, Jalil P, Ghulam U. Prevalence of Clinical Spectrum of Cutaneous Adverse Drug Reactions in Patients Presenting at a Tertiary Care Hospital in Pakistan. *Cureus*. 2021;13(4):e14568. doi:10.7759/cureus.14568
4. Crisafulli G, Franceschini F, Caimmi S, et al. Mild cutaneous reactions to drugs. *Acta Bio-Medica: Atenei Parmensis*. 2019;90(3-s):36-43.
5. Tempark T, John S, Rerknimitr P, Satapornpong P, Sukasem C. Drug-Induced Severe Cutaneous Adverse Reactions: Insights Into Clinical Presentation, Immunopathogenesis, Diagnostic Methods, Treatment, and Pharmacogenomics. *Front Pharmacol*. 2022;13:832048. doi:10.3389/fphar.2022.832048
6. Dibek Misirlioglu E, Guvenir H, Bahceci S, et al. Severe Cutaneous Adverse Drug Reactions in Pediatric Patients: A Multicenter Study. *J Allergy Clin Immunol Pract*. 2017;5(3):757-763. doi:10.1016/j.jaip.2017.02.013
7. Zhang C, Van DN, Hieu C, Craig T. Drug-induced severe cutaneous adverse reactions: Determine the cause and prevention. *Ann Allergy Asthma Immunol*. 2019;123(5):483-487. doi:10.1016/j.anai.2019.08.004
8. Perez CE, Dyer JA. Cutaneous Drug Eruptions in Pediatrics-A Primer. *Pediatr Ann*. 2020;49(3):e132-e139. doi:10.3928/19382359-20200224-01
9. Dilek N, Özkol HU, Akbaş A, et al. Cutaneous drug reactions in children: a multicentric study. *Postepy Dermatologii I Alergologii*. 2014;31(6):368-371. doi:10.5114/pdia.2014.43881
10. Borroni RG. Pharmacogenetic markers of severe cutaneous adverse drug reactions. *Giornale Italiano di Dermatologia e Venereologia: Organo Ufficiale, Societa Italiana di Dermatologia e Sifilografia*. 2014;149(2):219-226.
11. Jeimy S, Ben-Shoshan M, Abrams EM, Ellis AK, Connors L, Wong T. Practical guide for evaluation and management of beta-lactam allergy: position statement from the Canadian Society of Allergy and Clinical Immunology. *Allergy Asthma Clin Immunol: Off J Can Soc Allergy Clin Immunol*. 2020;16(1):95. doi:10.1186/s13223-020-00494-2
12. Roujeau JC. Re-evaluation of 'drug-induced' erythema multiforme in the medical literature. *Br J Dermatol*. 2016;175(3):650-651. doi:10.1111/bjd.14841
13. Del Pozzo-Magaña BR, Lazo-Langner A, Rieder MJ. Stevens-Johnson syndrome and toxic epidermal necrolysis. A comparison of outcomes between adults and children. *Eur J Pediatr Dermatol*. 2019;29(4):198-205.
14. Davis RL, Gallagher MA, Asgari MM, et al. Identification of Stevens-Johnson syndrome and toxic epidermal necrolysis in electronic health record databases. *Pharmacoepidemiol Drug Saf*. 2015;24(7):684-692. doi:10.1002/pds.3778
15. Talib NH, Leelavathi M, Hamzah Z. Common adverse cutaneous drug reaction patterns and the causative drugs in Malaysia. *S Afr Fam Pract*. 2015;57(4):227-230. doi:10.1080/20786190.2015.1024026
16. Yang F, Chen Z, Chen S-A, et al. Clinical profile of cutaneous adverse drug reactions: a retrospective study of 1883 hospitalized patients from 2007 to 2016 in Shanghai. *China Eur J Dermatol*. 2020;30(1):24-31. doi:10.1684/ejd.2020.3713
17. Sharma S, Jayakumar D, Palappallil DS. Pharmacovigilance of Cutaneous Adverse Drug Reactions among Patients Attending Dermatology Department at a Tertiary Care Hospital. *Indian Dermatol Online J*. 2019;10(5):547-554. doi:10.4103/idoj.IDOJ_419_18
18. Campos-Fernández Mdel M, Ponce-De-León-Rosales S, Archer-Dubon C, Orozco-Topete R. Incidence and risk factors for cutaneous adverse drug reactions in an intensive care unit. *Revista de Investigacion Clinica; Organo del Hospital de Enfermedades de la Nutricion*. 2005;57(6):770-774.
19. Nayak S, Acharjya B. Adverse cutaneous drug reaction. *Indian J Dermatol*. 2008;53(1):2-8. doi:10.4103/0019-5154.39732
20. Ponzo MG, Miliszewski M, Kirchhof MG, Keown PA, Dutz JP. HLA-B*58:01 Genotyping to Prevent Cases of DRESS and SJS/TEN in East Asians Treated with Allopurinol—A Canadian Missed Opportunity. *J Cutan Med Surg*. 2019;23(6):595-601. doi:10.1177/1203475419867599
21. Ksouda K, Affes H, Mahfoudh N, et al. HLA-A*31:01 and carbamazepine-induced DRESS syndrom in a sample of North African population. *Seizure*. 2017;53:42-46. doi:10.1016/j.seizure.2017.10.018
22. Rawlins MD. Clinical pharmacology. Adverse reactions to drugs. *Br Med J (Clin Res Ed)*. 1981;282(6268):974-976. doi:10.1136/bmj.282.6268.974
23. Wyatt AJ, Leonard GD, Sachs DL. Cutaneous reactions to chemotherapy and their management. *Am J Clin Dermatol*. 2006;7(1):45-63. doi:10.2165/00128071-200607010-00005

13652125, 2024, 8, Downloaded from https://bpspubs.onlinelibrary.wiley.com/doi/10.1111/bcp.15490, Wiley Online Library on [18/08/2025]. See the Terms and Conditions (https://onlinelibrary.wiley.com/terms-and-conditions) on Wiley Online Library for rules of use; OA articles are governed by the applicable Creative Commons License

24. Saif MW, Elfiky AA. Identifying and treating fluoropyrimidine-associated hand-and-foot syndrome in white and non-white patients. *J Support Oncol*. 2007;5(7):337-343.
25. van Doorn L, Veelenturf S, Binkhorst L, Bins S, Mathijssen R. Capecitabine and the Risk of Fingerprint Loss. *JAMA Oncol*. 2017;3(1):122-123. doi:10.1001/jamaoncol.2016.2638
26. Nagore E, Insa A, Sanmartín O. Antineoplastic therapy-induced palmar plantar erythrodysesthesia ('hand-foot') syndrome. Incidence, recognition and management. *Am J Clin Dermatol*. 2000;1(4):225-234. doi:10.2165/00128071-200001040-00004
27. Lassere Y, Hoff P. Management of hand-foot syndrome in patients treated with capecitabine (Xeloda). *Eur J Oncol Nurs off J Eur Oncol Nurs Soc*. 2004;8(Suppl 1):S31-S40. doi:10.1016/j.ejon.2004.06.007
28. Kwakman JJM, Elshot YS, Punt CJA, Koopman M. Management of cytotoxic chemotherapy-induced hand-foot syndrome. *Oncology Reviews*. 2020;14(1):442. doi:10.4081/oncol.2020.442
29. Martschick A, Sehouli J, Patzelt A, et al. The pathogenetic mechanism of anthracycline-induced palmar-plantar erythrodysesthesia. *Anticancer Res*. 2009;29(6):2307-2313.
30. Lou Y, Wang Q, Zheng J, et al. Possible Pathways of Capecitabine-Induced Hand-Foot Syndrome. *Chem Res Toxicol*. 2016;29(10):1591-1601. doi:10.1021/acs.chemrestox.6b00215
31. Ziemer M, Goetze S, Juhasz K, Elsner P. Flagellate dermatitis as a bleomycin-specific adverse effect of cytostatic therapy: a clinical-histopathologic correlation. *Am J Clin Dermatol*. 2011;12(1):68-76. doi:10.2165/11537080-000000000-00000
32. Turan Erkek E, Karaali CN, Yılmaz G, Gültürk E. Bleomycin-Induced Flagellate Dermatitis. *Turkish J Haematol off J Turkish Soc Haematol*. 2019;36(2):138-140. doi:10.4274/tjh.galenos.2019.2018.0317
33. Chaveli-López B, Bagán-Sebastián JV. Treatment of oral mucositis due to chemotherapy. *J Clin Exp Dentistry*. 2016;8(2):e201-e209. doi:10.4317/jced.52917
34. Piraccini BM, Iorizzo M, Rech G, Tosti A. Drug-induced hair disorders. *Curr Drug Saf*. 2006;1(3):301-305. doi:10.2174/157488606777934477
35. Macdonald JB, Macdonald B, Golitz LE, LoRusso P, Sekulic A. Cutaneous adverse effects of targeted therapies: Part I: Inhibitors of the cellular membrane. *J Am Acad Dermatol*. 2015;72(2):203-218; quiz 19–20. doi:10.1016/j.jaad.2014.07.033
36. Reyes-Habito CM, Roh EK. Cutaneous reactions to chemotherapeutic drugs and targeted therapy for cancer: Part II. Targeted therapy. *J Am Acad Dermatol*. 2014;71(2):217.e1-.e11. quiz 27-8. doi:10.1016/j.jaad.2014.04.013
37. Kim KB, Kefford R, Pavlick AC, et al. Phase II study of the MEK1/-MEK2 inhibitor Trametinib in patients with metastatic BRAF-mutant cutaneous melanoma previously treated with or without a BRAF inhibitor. *J Clin Oncol*. 2013;31(4):482-489. doi:10.1200/JCO.2012.43.5966
38. Long GV, Flaherty KT, Stroyakovskiy D, et al. Dabrafenib plus trametinib versus dabrafenib monotherapy in patients with metastatic BRAF V600E/K-mutant melanoma: long-term survival and safety analysis of a phase 3 study. *Annals Oncol off J Eur Soc Med Oncol*. 2017;28(7):1631-1639. doi:10.1093/annonc/mdx176
39. Mayorga C, Fernandez TD, Montañez MI, Moreno E, Torres MJ. Recent developments and highlights in drug hypersensitivity. *Allergy*. 2019;74(12):2368-2381. doi:10.1111/all.14061
40. Franceschini F, Bottau P, Caimmi S, et al. Mechanisms of hypersensitivity reactions induced by drugs. *Acta Bio-Medica: Atenei Parmensis*. 2019;90(3-s):44-51. doi:10.23750/abm.v90i3-S.8160
41. Marwa K, Kondamudi NP. *Type IV Hypersensitivity Reaction*. StatPearls. Treasure Island (FL): StatPearls Publishing Copyright © 2022, StatPearls Publishing LLC; 2022.
42. Chen CB, Abe R, Pan RY, et al. An Updated Review of the Molecular Mechanisms in Drug Hypersensitivity. *J Immunol Res*. 2018;2018:6431694. doi:10.1155/2018/6431694
43. Pichler WJ (Ed) Drug Hypersensitivity Reactions: Classification and Relationship to T-Cell Activation, 2007.
44. Zambernardi A, Label M. Cutaneous Adverse Drug Reactions: How to Identify the Trigger. *Actas Dermo-Sifiliograficas*. 2018;109(8):699-707. doi:10.1016/j.ad.2018.02.017
45. Escribese MM, Rosace D, Chivato T, Fernández TD, Corbí AL, Barber D. *Alternative Anaphylactic Routes: The Potential Role of Macrophages. Frontiers in immunology*. Vol. 8; 2017:8. doi:10.3389/fimmu.2017.00515.
46. Torres MJ, Mayorga C, Fernández TD, et al. T cell assessment in allergic drug reactions during the acute phase according to the time of occurrence. *Int J Immunopathol Pharmacol*. 2006;19(1):119-130. doi:10.1177/205873920601900112
47. Szebeni J. Complement activation-related pseudoallergy: a stress reaction in blood triggered by nanomedicines and biologicals. *Mol Immunol*. 2014;61(2):163-173. doi:10.1016/j.molimm.2014.06.038
48. Zhang B, Li Q, Shi C, Zhang X. Drug-Induced Pseudoallergy: A Review of the Causes and Mechanisms. *Pharmacology*. 2018;101(1–2):104-110. doi:10.1159/000479878
49. Warrington R, Silviu-Dan F, Wong T. Drug allergy. *Allergy Asthma Clin Immunol*. 2018;14(2):60. doi:10.1186/s13223-018-0289-y
50. Kumar M, Duraisamy K, Chow B-K-C. Unlocking the Non-IgE-Mediated Pseudo-Allergic Reaction Puzzle with Mas-Related G-Protein Coupled Receptor Member X2 (MRGPRX2). *Cell*. 2021;10(5):1033. doi:10.3390/cells10051033
51. Heelan K, Shear NH. Cutaneous drug reactions in children: an update. *Paediatr Drugs*. 2013;15(6):493-503. doi:10.1007/s40272-013-0039-z
52. Manvi S, Mahajan VK, Mehta KS, et al. The Clinical Characteristics, Putative Drugs, and Optimal Management of 62 Patients With Stevens-Johnson Syndrome and/or Toxic Epidermal Necrolysis: A Retrospective Observational Study. *Indian Dermatol Online J*. 2022;13(1):23-31. doi:10.4103/idoj.idoj_530_21
53. Bastuji-Garin S, Rzany B, Stern RS, Shear NH, Naldi L, Roujeau JC. Clinical classification of cases of toxic epidermal necrolysis, Stevens-Johnson syndrome, and erythema multiforme. *Arch Dermatol*. 1993;129(1):92-96. doi:10.1001/archderm.1993.01680220104023
54. Roujeau J-C. Chapter 39. Erythema Multiforme. In: Goldsmith LA, Katz SI, Gilchrest BA, Paller AS, Leffell DJ, Wolff K, eds. *Fitzpatrick's Dermatology in General Medicine*. 8th ed. New York, NY: The McGraw-Hill Companies; 2012.
55. Song JE, Sidbury R. An update on pediatric cutaneous drug eruptions. *Clin Dermatol*. 2014;32(4):516-523. doi:10.1016/j.clindermatol.2014.02.005
56. Waldman R, Whitaker-Worth D, Grant-Kels JM. Cutaneous adverse drug reactions: Kids are not just little people. *Clin Dermatol*. 2017;35(6):566-582. doi:10.1016/j.clindermatol.2017.08.007
57. Newell BD, Horii KA. Cutaneous drug reactions in children. *Pediatr Ann*. 2010;39(10):618-625. doi:10.3928/00904481-20100922-10
58. Mohapatra M, Panda M, Kar BR, Raj C. Symmetric Drug-related Intertriginous and Flexural Exanthema due to Itraconazole: An Uncommon Side Effect of a Commonly Used Drug. *Indian Dermatol Online J*. 2017;8(6):501-503. doi:10.4103/idoj.IDOJ_179_17
59. Tan SC, Tan JW. Symmetrical drug-related intertriginous and flexural exanthema. *Curr Opin Allergy Clin Immunol*. 2011;11(4):313-318. doi:10.1097/ACI.0b013e3283489d5f
60. Harbaoui S, Litaiem N. *Symmetrical Drug-related Intertriginous and Flexural Exanthema*. StatPearls. Treasure Island (FL): StatPearls Publishing Copyright © 2022, StatPearls Publishing LLC; 2022.
61. Silva-Feistner M, Ortiz E, Rojas-Lechuga MJ, Muñoz D. DRESS syndrome in paediatrics: Clinical case. *Rev Chil Pediatr*. 2017;88(1):158-163. doi:10.1016/j.rchipe.2016.05.010

13652125, 2024, 8, Downloaded from https://bpspubs.onlinelibrary.wiley.com/doi/10.1111/bcp.15490, Wiley Online Library on [18/08/2025]. See the Terms and Conditions (https://onlinelibrary.wiley.com/terms-and-conditions) on Wiley Online Library for rules of use; OA articles are governed by the applicable Creative Commons License

62. Erdem SB, Nacaroglu HT, Bag O, Karkiner CS, Korkmaz HA, Can D. DRESS syndrome associated with type 2 diabetes in a child. *Central-Eur J Immunol*. 2015;40(4):493-496. doi:10.5114/ceji.2015.54606
63. Pavlos R, Mallal S, Ostrov D, Pompeu Y, Phillips E. Fever, rash, and systemic symptoms: understanding the role of virus and HLA in severe cutaneous drug allergy. *J Allergy Clin Immunol Pract*. 2014; 2(1):21-33. doi:10.1016/j.jaip.2013.11.005
64. Criado PR, Criado RF, Avancini JM, Santi CG. Drug reaction with Eosinophilia and Systemic Symptoms (DRESS) /Drug-induced Hypersensitivity Syndrome (DIHS): a review of current concepts. *An Bras Dermatol*. 2012;87(3):435-449. doi:10.1590/S0365-05962012000300013
65. Vasanthan T, Rajaguru G, Venkatesh C, Narayanan P, Gulati R, Toi P. DRESS Syndrome with Peripheral Neuropathy Due to Reactivation of Cytomegalovirus in a Child. *J Glob Infect*. 2015;7(2):89-90. doi:10.4103/0974-777X.157249
66. Mori F, Caffarelli C, Caimmi S, et al. Drug reaction with eosinophilia and systemic symptoms (DRESS) in children. *Acta Bio-Medica: Atenei Parmensis*. 2019;90(3-s):66-79. doi:10.23750/abm.v90i3-S.8167
67. Castellazzi ML, Esposito S, Claut LE, Daccò V, Colombo C. Drug reaction with eosinophilia and systemic symptoms (DRESS) syndrome in two young children: the importance of an early diagnosis. *Ital J Pediatr*. 2018;44(1):93. doi:10.1186/s13052-018-0535-4
68. Shiohara T, Mizukawa Y. Drug-induced hypersensitivity syndrome (DiHS)/drug reaction with eosinophilia and systemic symptoms (DRESS): An update in 2019. *Allergol Int*. 2019;68(3):301-308. doi:10.1016/j.alit.2019.03.006
69. Matta JM, Flores SM, Cherit JD. Drug reaction with eosinophilia and systemic symptoms (DRESS) and its relation with autoimmunity in a reference center in Mexico. *An Bras Dermatol*. 2017;92(1):30-33. doi:10.1590/abd1806-4841.20175190
70. Zuberbier T, Aberer W, Asero R, et al. The EAACI/GA^{2}LEN/EDF/-WAO guideline for the definition, classification, diagnosis and management of urticaria. *Allergy*. 2018;73(7):1393-1414. doi:10.1111/all.13397
71. Langley EW, Gigante J. Anaphylaxis, Urticaria, and Angioedema. *Pediatr Rev*. 2013;34(6):247-257. doi:10.1542/pir.34.6.247
72. Alhawal S, Aldarwish M, Almoosa Z. Serum Sickness following Tetanus Toxoid Injection. *Case Rep Pediatr*. 2021;2021:6680979. doi:10.1155/2021/6680979
73. Fouda GE, Bavbek S. Rituximab Hypersensitivity: From Clinical Presentation to Management. *Front Pharmacol*. 2020;11:572863. doi:10.3389/fphar.2020.572863
74. Usman N, Annamaraju P. *Type III Hypersensitivity Reaction*. StatPearls. Treasure Island (FL): StatPearls Publishing Copyright © 2022, StatPearls Publishing LLC; 2022.
75. Rixe N, Tavarez MM. *Serum Sickness*. StatPearls. Treasure Island (FL): StatPearls Publishing Copyright © 2022, StatPearls Publishing LLC; 2022.
76. Del Pozzo-Magaña BR, Lazo-Langner A, Dermatol E. Serum sickness-like reaction in children: Review of the literature. *EMJ Dermatol*. 2019;7(1):106-111.
77. Del Pozzo-Magaña BR, Abuzgaia A, Murray B, Rieder MJ, Lazo-Langner A. Paediatric serum sickness-like reaction: A 10-year retrospective cohort study. *Paediatr Child Health*. 2021;26(7):428-435. doi:10.1093/pch/pxab003
78. Abdelbaset A, Elzagallaai AMA, Del Pozzo-Magaña BR, Loubani E, Rieder MJ. The Role of In Vitro Testing in Signal to Noise Analysis in Pharmacovigilance: ß-Lactam-induced Serum Sickness-Like Reaction. *Frontiers in Phamacology*. 2022. Submitted.
79. Isaacs D. Serum sickness-like reaction to cefaclor. *J Paediatr Child Health*. 2001;37(3):298-299. doi:10.1046/j.1440-1754.2001.00632.x
80. Shimizu R, Tsushima F, Komiya R, Yamagata Y, Harada H. Fixed Drug Eruption Associated with Nonsteroidal Anti-Inflammatory Drugs for Menstrual Pain: A Case Report. *Case Rep Dermatol*. 2022;14(1):6-11. doi:10.1159/000520534
81. Ben Fadhel N, Chaabane A, Ammar H, et al. Clinical features, culprit drugs, and allergology workup in 41 cases of fixed drug eruption. *Contact Dermatitis*. 2019;81(5):336-340. doi:10.1111/cod.13351
82. Mitre V, Applebaum DS, Albahrani Y, Hsu S. Generalized bullous fixed drug eruption imitating toxic epidermal necrolysis: a case report and literature review. *Dermatol Online J*. 2017;23(7). doi:10.5070/D3237035734
83. Anderson HJ, Lee JB. A Review of Fixed Drug Eruption with a Special Focus on Generalized Bullous Fixed Drug Eruption. *Medicina (Kaunas)*. 2021;57(9). doi:10.3390/medicina57090925
84. Stavropoulos PG, Soura E, Antoniou C. Drug-induced pemphigoid: a review of the literature. *J Eur Acad Dermatol Venereol: JEADV*. 2014; 28(9):1133-1140. doi:10.1111/jdv.12366
85. Tasanen K, Varpuluoma O, Nishie W. Dipeptidyl Peptidase-4 Inhibitor-Associated Bullous Pemphigoid. *Front Immunol*. 2019;10: 1238. doi:10.3389/fimmu.2019.01238
86. Verheyden MJ, Bilgic A, Murrell DF. A Systematic Review of Drug-Induced Pemphigoid. *Acta Derm Venereol*. 2020;100(15):adv00224. doi:10.2340/00015555-3457
87. Liotti L, Caimmi S, Bottau P, et al. Clinical features, outcomes and treatment in children with drug induced Stevens-Johnson syndrome and toxic epidermal necrolysis. *Acta Bio-Medica: Atenei Parmensis*. 2019;90(3-s):52-60.
88. Oakley AM, Krishnamurthy K. *Stevens Johnson Syndrome*. StatPearls. Treasure Island (FL): StatPearls Publishing Copyright © 2022, StatPearls Publishing LLC; 2022.
89. Ramien M, Goldman JL. Pediatric SJS-TEN: Where are we now? *F1000Research*. 2020;9:F1000 Faculty Rev-982.
90. Shibata T, Muto J, Hirano Y, et al. Palmoplantar pustulosis-like eruption following tofacitinib therapy for juvenile idiopathic arthritis. *JAAD Case Reports*. 2019;5(6):518-521. doi:10.1016/j.jdcr.2019.03.024
91. Koumaki D, Koumaki V, Lagoudaki E, Bertsias G. Palmoplantar Pustulosis-like Eruption Induced by Baricitinib for Treatment of Rheumatoid Arthritis. *Eur J Case Rep Internal Med*. 2020;7(1): 001383. doi:10.12890/2019_001383
92. Freitas E, Rodrigues MA, Torres T. Diagnosis, Screening and Treatment of Patients with Palmoplantar Pustulosis (PPP): A Review of Current Practices and Recommendations. *Clin Cosmetic Investig Dermatol*. 2020;13:561-578. doi:10.2147/CCID.S240607
93. Hiraiwa T, Yamamoto T. Nail involvement associated with palmoplantar pustulosis. *Int J Dermatol*. 2017;56(2):e28-e29. doi:10.1111/ijd.13224
94. Misiak-Galazka M, Zozula J, Rudnicka L. Palmoplantar Pustulosis: Recent Advances in Etiopathogenesis and Emerging Treatments. *Am J Clin Dermatol*. 2020;21(3):355-370. doi:10.1007/s40257-020-00503-5
95. De A, Das S, Sarda A, Pal D, Biswas P. Acute Generalised Exanthematous Pustulosis: An Update. *Indian J Dermatol*. 2018;63(1):22-29. doi:10.4103/ijd.IJD_581_17
96. Feldmeyer L, Heidemeyer K, Yawalkar N. Acute Generalized Exanthematous Pustulosis: Pathogenesis, Genetic Background, Clinical Variants and Therapy. *Int J Mol Sci*. 2016;17(8). doi:10.3390/ijms17081214
97. Copaescu A, Gibson A, Li Y, Trubiano JA, Phillips EJ. An Updated Review of the Diagnostic Methods in Delayed Drug Hypersensitivity. *Front Pharmacol*. 2021;11. doi:10.3389/fphar.2020.573573
98. Sidoroff A, Halevy S, Bavinck JN, Vaillant L, Roujeau JC. Acute generalized exanthematous pustulosis (AGEP) - A clinical reaction pattern. *J Cutan Pathol*. 2001;28(3):113-119. doi:10.1034/j.1600-0560.2001.028003113.x

13652125, 2024, 8, Downloaded from https://bpspubs.onlinelibrary.wiley.com/doi/10.1111/bcp.15490, Wiley Online Library on [18/08/2025]. See the Terms and Conditions (https://onlinelibrary.wiley.com/terms-and-conditions) on Wiley Online Library for rules of use; OA articles are governed by the applicable Creative Commons License

99. Szatkowski J, Schwartz RA. Acute generalized exanthematous pustulosis (AGEP): A review and update. *J Am Acad Dermatol*. 2015;73(5):843-848. doi:10.1016/j.jaad.2015.07.017
100. Villani A, Baldo A, De Fata Salvatores G, Desiato V, Ayala F, Donadio C. Acute Localized Exanthematous Pustulosis (ALEP): Review of Literature with Report of Case Caused by Amoxicillin-Clavulanic Acid. *Dermatol Ther*. 2017;7(4):563-570. doi:10.1007/s13555-017-0206-1
101. He Y, Sawalha AH. Drug-induced lupus erythematosus: an update on drugs and mechanisms. *Curr Opin Rheumatol*. 2018;30(5):490-497. doi:10.1097/BOR.0000000000000522
102. Katz U, Zandman-Goddard G. Drug-induced lupus: an update. *Autoimmun Rev*. 2010;10(1):46-50. doi:10.1016/j.autrev.2010.07.005
103. Solhjoo M, Goyal A, Chauhan K. *Drug-Induced Lupus Erythematosus*. StatPearls. Treasure Island (FL): StatPearls Publishing Copyright © 2022, StatPearls Publishing LLC; 2022.
104. Radić M, Martinović Kaliterna D, Radić J. Drug-induced vasculitis: a clinical and pathological review. *Neth J Med*. 2012;70(1):12-17.
105. Doyle MK, Cuellar ML. Drug-induced vasculitis. *Expert Opin Drug Saf*. 2003;2(4):401-409. doi:10.1517/14740338.2.4.401
106. Altomare M, Jaulent C, Hacard F, Nicolas JF, Berard F, Nosbaum A. Drug-induced cutaneous leukocytoclastic vasculitis: a series of 5 cases. *World Allergy Org J*. 2020;13(8):100244. doi:10.1016/j.waojou.2020.100244
107. Kalpana B, Satish M, Jaya A, Ena S, Philip AC, Imran U. Drug-induced leukocytoclastic vasculitis: tigecycline a rare cause. *Southwest Resp Crit Care Chron*. 2015;3(9). doi:10.12746/swrccc2015.0309.123
108. Monteiro AF, Rato M, Martins C. Drug-induced photosensitivity: Photoallergic and phototoxic reactions. *Clin Dermatol*. 2016;34(5):571-581. doi:10.1016/j.clindermatol.2016.05.006
109. Lozzi F, Di Raimondo C, Lanna C, et al. Latest Evidence Regarding the Effects of Photosensitive Drugs on the Skin: Pathogenetic Mechanisms and Clinical Manifestations. *Pharmaceutics*. 2020;12(11). doi:10.3390/pharmaceutics12111104
110. Kowalska J, Rok J, Rzepka Z, Wrześniok D. Drug-Induced Photosensitivity-From Light and Chemistry to Biological Reactions and Clinical Symptoms. *Pharmaceuticals (Basel, Switzerland)*. 2021;14(8). doi:10.3390/ph14080723
111. Hofmann GA, Weber B. Drug-induced photosensitivity: culprit drugs, potential mechanisms and clinical consequences. Journal der Deutschen Dermatologischen Gesellschaft =. *J German Soc Dermatol JDDG*. 2021;19(1):19-29. doi:10.1111/ddg.14314
112. Di Bartolomeo L, Irrera N, Campo GM, et al. Drug-Induced Photosensitivity: Clinical Types of Phototoxicity and Photoallergy and Pathogenetic Mechanisms. *Frontiers in Allergy*. 2022;3. doi:10.3389/falgy.2022.876695
113. Al Aboud DM, Nessel TA, Hafsi W. *Cutaneous Adverse Drug Reaction*. StatPearls. Treasure Island (FL): StatPearls Publishing Copyright © 2022, StatPearls Publishing LLC; 2022.
114. Riedl MA, Casillas AM. Adverse drug reactions: types and treatment options. *Am Fam Physician*. 2003;68(9):1781-1790.
115. Copaescu AM, Trublano JA. The assessment of severe cutaneous adverse drug reactions. *Australian Prescriber*. 2022;45(2):43-48. doi:10.18773/austprescr.2022.010
116. Kardaun SH, Sekula P, Valeyrie-Allanore L, et al. Drug reaction with eosinophilia and systemic symptoms (DRESS): an original multisystem adverse drug reaction. Results from the prospective RegiSCAR study. *Br J Dermatol*. 2013;169(5):1071-1080. doi:10.1111/bjd.12501
117. Shiohara T, Inaoka M, Kano Y. Drug-induced hypersensitivity syndrome (DIHS): a reaction induced by a complex interplay among herpesviruses and antiviral and antidrug immune responses. *Allergol Int off J Japan Soc Allergol*. 2006;55(1):1-8. doi:10.2332/allergolint.55.1
118. Naranjo CA, Busto U, Sellers EM, et al. A method for estimating the probability of adverse drug reactions. *Clin Pharmacol Ther*. 1981;30(2):239-245. doi:10.1038/clpt.1981.154
119. Gallagher RM, Kirkham JJ, Mason JR, et al. Development and Inter-Rater Reliability of the Liverpool Adverse Drug Reaction Causality Assessment Tool. *PLoS ONE*. 2011;6(12):e28096. doi:10.1371/journal.pone.0028096
120. Sassolas B, Haddad C, Mockenhaupt M, et al. ALDEN, an algorithm for assessment of drug causality in Stevens-Johnson Syndrome and toxic epidermal necrolysis: comparison with case-control analysis. *Clin Pharmacol Ther*. 2010;88(1):60-68. doi:10.1038/clpt.2009.252
121. Das S, Biswas P, Pal D, De A. Stamping a Case of Cutaneous Adverse Drug Reaction: Proving Beyond Causality Assessment. *Indian J Dermatol*. 2018;63(2):99-106. doi:10.4103/ijd.IJD_580_17
122. Bousquet PJ, Gaeta F, Bousquet-Rouanet L, Lefrant JY, Demoly P, Romano A. Provocation tests in diagnosing drug hypersensitivity. *Curr Pharm Des*. 2008;14(27):2792-2802. doi:10.2174/138161208786369731
123. Soyer O, Sahiner UM, Sekerel BE. Pro and Contra: Provocation Tests in Drug Hypersensitivity. *Int J Mol Sci*. 2017;18(7). doi:10.3390/ijms18071437
124. Barbaud A, Collet E, Milpied B, et al. A multicentre study to determine the value and safety of drug patch tests for the three main classes of severe cutaneous adverse drug reactions. *Br J Dermatol*. 2013;168(3):555-562. doi:10.1111/bjd.12125
125. Brockow K, Pfützner W. Cutaneous drug hypersensitivity: developments and controversies. *Curr Opin Allergy Clin Immunol*. 2019;19(4):308-318. doi:10.1097/ACI.0000000000000548
126. Brockow K, Romano A. Skin tests in the diagnosis of drug hypersensitivity reactions. *Curr Pharm Des*. 2008;14(27):2778-2791. doi:10.2174/138161208786369821
127. Pinho A, Coutinho I, Gameiro A, Gouveia M, Gonçalo M. Patch testing - a valuable tool for investigating non-immediate cutaneous adverse drug reactions to antibiotics. *J Eur Acad Dermatol Venereol JEADV*. 2017;31(2):280-287. doi:10.1111/jdv.13796
128. Mayorga C, Celik G, Rouzaire P, et al. In vitro tests for drug hypersensitivity reactions: an ENDA/EAACI Drug Allergy Interest Group position paper. *Allergy*. 2016;71(8):1103-1134. doi:10.1111/all.12886
129. Brönnimann M, Yawalkar N. Histopathology of drug-induced exanthems: is there a role in diagnosis of drug allergy? *Curr Opin Allergy Clin Immunol*. 2005;5(4):317-321. doi:10.1097/01.all.0000173787.65777.77
130. Ernst M, Giubellino A. Histopathologic Features of Maculopapular Drug Eruption. *Dermatopathology (Basel, Switzerland)*. 2022;9(2):111-121. doi:10.3390/dermatopathology9020014
131. Doña I, Torres MJ, Montañez MI, Fernández TD. In Vitro Diagnostic Testing for Antibiotic Allergy. *Allergy Asthma Immunol Res*. 2017;9(4):288-298. doi:10.4168/aair.2017.9.4.288
132. Sousa-Pinto B, Tarrio I, Blumenthal KG, et al. Accuracy of penicillin allergy diagnostic tests: A systematic review and meta-analysis. *J Allergy Clin Immunol*. 2021;147(1):296-308. doi:10.1016/j.jaci.2020.04.058
133. Fontaine C, Mayorga C, Bousquet PJ, et al. Relevance of the determination of serum-specific IgE antibodies in the diagnosis of immediate beta-lactam allergy. *Allergy*. 2007;62(1):47-52. doi:10.1111/j.1398-9995.2006.01268.x
134. Pichler WJ, Tilch J. The lymphocyte transformation test in the diagnosis of drug hypersensitivity. *Allergy*. 2004;59(8):809-820. doi:10.1111/j.1398-9995.2004.00547.x
135. Cabañas R, Calderón O, Ramírez E, et al. Sensitivity and specificity of the lymphocyte transformation test in drug reaction with eosinophilia and systemic symptoms causality assessment. *Clin Exp Allergy Journal British Soc Allergy Clin Immunol*. 2018;48(3):325-333. doi:10.1111/cea.13076

13652125, 2024, 8, Downloaded from https://bpspubs.onlinelibrary.wiley.com/doi/10.1111/bcp.15490, Wiley Online Library on [18/08/2025]. See the Terms and Conditions (https://onlinelibrary.wiley.com/terms-and-conditions) on Wiley Online Library for rules of use; OA articles are governed by the applicable Creative Commons License

136. Karami Z, Mesdaghi M, Karimzadeh P, et al. Evaluation of Lymphocyte Transformation Test Results in Patients with Delayed Hypersensitivity Reactions following the Use of Anticonvulsant Drugs. *Int Arch Allergy Immunol*. 2016;170(3):158-162. doi:10.1159/000448284
137. Elzagallaai AA, Jahedmotlagh Z, Del Pozzo-Magaña BR, et al. Predictive value of the lymphocyte toxicity assay in the diagnosis of drug hypersensitivity syndrome. *Mol Diagn Ther*. 2010;14(5):317-322. doi:10.1007/BF03256387
138. Elzagallaai AA, Rieder MJ. In vitro testing for diagnosis of idiosyncratic adverse drug reactions: Implications for pathophysiology. *Br J Clin Pharmacol*. 2015;80(4):889-900. doi:10.1111/bcp.12505
139. Kim SY, Kim JH, Jang YS, et al. The Basophil Activation Test Is Safe and Useful for Confirming Drug-Induced Anaphylaxis. *Allergy, Asthma Immunol Res*. 2016;8(6):541-544. doi:10.4168/aair.2016.8.6.541
140. Copaescu A, Choshi P, Pedretti S, Mouhtouris E, Peter J, Trubiano JA. Dose Dependent Antimicrobial Cellular Cytotoxicity-Implications for ex vivo Diagnostics. *Front Pharmacol*. 2021;12:640012. doi:10.3389/fphar.2021.640012
141. Porebski G, Piotrowicz-Wojcik K, Spiewak R. ELISpot assay as a diagnostic tool in drug hypersensitivity reactions. *J Immunol Methods*. 2021;495:113062. doi:10.1016/j.jim.2021.113062
142. Böhm R, Proksch E, Schwarz T, Cascorbi I. Drug Hypersensitivity. *Deutsches Arzteblatt Int*. 2018;115(29–30):501-512. doi:10.3238/arztebl.2018.0501

How to cite this article: Del Pozzo-Magaña BR, Liy-Wong C. Drugs and the skin: A concise review of cutaneous adverse drug reactions. *Br J Clin Pharmacol*. 2024;90(8):1838-1855. doi:10.1111/bcp.15490

13652125, 2024, 8, Downloaded from https://bpspubs.onlinelibrary.wiley.com/doi/10.1111/bcp.15490, Wiley Online Library on [18/08/2025]. See the Terms and Conditions (https://onlinelibrary.wiley.com/terms-and-conditions) on Wiley Online Library for rules of use; OA articles are governed by the applicable Creative Commons License