CME

# Red flags of low back pain

**Michael G. DePalma, MHS, PA-C, DFAAPA**


## ABSTRACT

Low back pain is a frequent complaint of patients seeking care at private offices, ambulatory clinics, and EDs. Key signs and symptoms can guide clinicians in differentiating acute and persistent mechanical low back pain from back pain resulting from a specific cause. Awareness of these findings can reduce the number of missed or incorrect diagnoses that lead to poor patient outcomes. The ability to recognize the red flag findings of serious causes of low back pain ensures prompt diagnosis and initiation of appropriate treatment. This article highlights the history and physical examination findings that will improve identification of red flags associated with emergency or serious causes.


**Keywords:** low back pain, lumbar, red flags, signs, symptoms, emergency

## Learning objectives

- Explain which portions of a patient's history that might serve as red flags for pathologic causes of low back pain.
- Describe the elements of the physical examination that may serve as red flags for pathologic causes of low back pain.

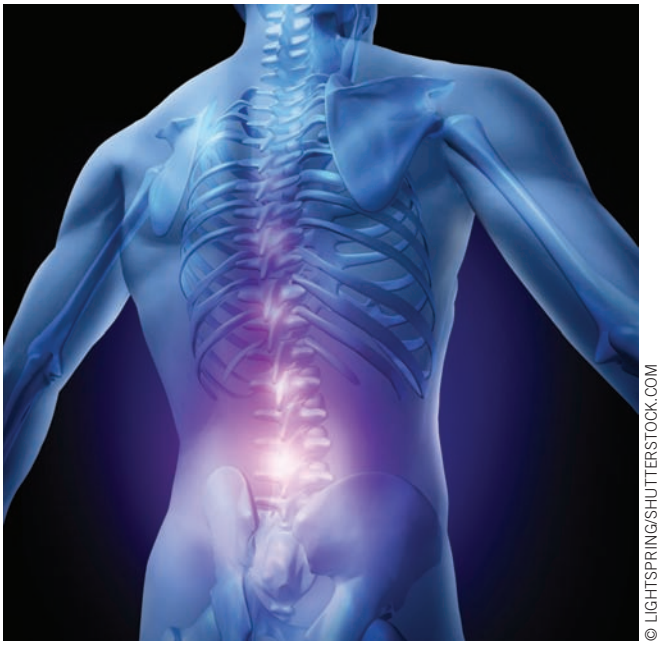

© LIGHTSPRING/SHUTTERSTOCK.COM

Low back pain is an increasingly common reason that patients seek visits with healthcare providers, and a leading cause of disability globally, with an estimated worldwide incidence of 7.3%.[1,2] Recent trends of patients seeking care for low back pain demonstrate an upsurge in urgent care and ambulatory care visits, although ED visits have declined slightly.[3,4] According to the CDC, back-related complaints accounted for more than 3.6 million visits to EDs and more than 5.7 million encounters at urgent and ambulatory care clinics in 2016.[4]

The most common form of low back pain is designated nonspecific or mechanical, because it lacks a pathoanatomic cause.[5] Most nonspecific back pain cases are self-limiting, resolve in 4 to 6 weeks, and are the cause of an estimated 90% of lumbar complaints.[5] Serious pathology can exist in some patients, and critical diagnoses often are missed on initial presentation. Reasons contributing to missed diagnoses include cognitive errors, knowledge gaps, and overlooked signs and symptoms.[6] Given the frequency of patients presenting with back pain, clinicians must perform a thorough evaluation of patients with lumbar complaints. Identifying risk factors and performing a complete review of systems and detailed physical examination (particularly of the musculoskeletal and neurologic systems) are essential components of evaluating patients presenting with back pain.

General risk factors for low back pain include age, sex, poor general health, physical stress on the spine, and psychologic stress.[7] Specific causes of low back pain that suggest emergency pathology include infection, malignancy, fractures or trauma, and spinal cord or nerve root compression (**Table 1**).[8] Signs and symptoms in patients with pathologic causes of low back pain are known as *red flags* and are the hallmark findings clinicians should use in evaluating these patients. Failure to recognize serious causes early on results in delayed testing and treatment, and may increase patient morbidity and mortality.

**Michael G. DePalma** is an assistant professor in the PA program at Lock Haven University in Harrisburg, Pa. The author has disclosed no potential conflicts of interest, financial or otherwise.

DOI:10.1097/01.JAA.0000684112.91641.4c

Copyright © 2020 American Academy of PAs



Copyright © 2020 American Academy of Physician Assistants

**Key points**

- Low back pain is a common musculoskeletal complaint treated in diverse settings.
- The ability to identify red-flag physical examination findings can help clinicians differentiate nonspecific low back pain from urgent causes, leading to earlier recognition and appropriate management.
- Prompt treatment is key to reducing patient morbidity and mortality from serious causes of low back pain.

## RED FLAGS IN THE HISTORY

A comprehensive evaluation of patients with low back pain includes a thorough history of present illness, past medical history, social and family history, and review of systems. Worrisome symptoms experienced by the patient often will guide the clinician to the appropriate diagnostic workup, based on the presentation.

**Age** Although older age is a general risk factor for back pain, the presence of acute back pain in patients under age 18 years or over age 50 years is a red flag and should be cause for concern.[9] Younger patients with or without a history of trauma presenting with acute back pain should be evaluated for congenital defects, spondylolysis, or vertebral fracture. Additional red flag findings in adolescents include night pain and weight loss, which are associated with serious pathologic outcomes and necessitate an evaluation for malignancy.[10] New-onset back pain in patients over age 50 years is concerning for tumor and infection, as well as intra-abdominal processes such as abdominal aortic aneurysm, pancreatitis, or nephrolithiasis.[9] Patients with osteoporosis are at high risk for vertebral compression fracture, which can occur with minimal or no trauma.[11] Maintain a high clinical suspicion of vertebral fracture in older adults who present with acute onset of low back pain.

**Anticoagulation or antiplatelet use** Obtain and review a comprehensive list of medications for each patient presenting with low back pain. Spinal cord and nerve root compression can result from epidural hematomas and present with acute low back pain in patients on oral anticoagulation therapy.[12] The incidence of spontaneous epidural hematoma is low; however, patients on anticoagulants or antiplatelets and those with thrombophilia are at a greater risk.[13]

**Fever** Inquire about and document any history of fever, chills, or recent illness in a patient with low back pain. Fever can be an indicator of infection and has a reported incidence of 66% to 83% in patients with spinal epidural abscesses.[9,14] The classic triad of fever, back pain, and neurologic deficit only is present in about 10% of patients with spinal epidural abscess.[15] However, any of the classic triad symptoms are of concern and should raise clinician suspicion for spinal epidural abscesses.[14,15] Dubosh and colleagues reported that the most commonly missed serious pathology of low back pain was an intraspinal or epidural abscess.[6] Spine infections in western societies have an incidence of 6.5 cases per 100,000 and have been reported to be increasing; therefore, always consider fever in a patient with back pain to be a red flag.[16]

**Genitourinary symptoms** Obtain a detailed genitourinary history, because urinary retention and bowel incontinence frequently are associated with cauda equina syndrome or nerve root impingement.[17] When questioned, patients with cauda equina syndrome frequently report sexual dysfunction and saddle anesthesia, which correlate with the disease.[17,18] Although most patients will not have emergency compression of the cauda equina, suspect this syndrome in patients presenting with acute low back pain or leg pain, and bowel or bladder dysfunction with or without saddle anesthesia.[19]

**Immunocompromise** Back pain in immunocompromised patients often presents a challenge for clinicians. Medications and comorbid conditions affecting the immune system cause an increased risk for pathologic causes. In addition, symptoms such as fever may not be present in an immunocompromised patient, which contributes to the difficult nature of assessing this patient population. Patients with a history of IV drug abuse, endocarditis, on hemodialysis, or with long-term central or peripheral venous access are at a higher risk for developing an infection.[14,16,20] Other conditions such as alcohol abuse, malnutrition, chronic corticosteroid use, and diabetes can increase patient susceptibility to spinal infection and vertebral compression fractures.[8] Be suspicious of a more serious cause of low back pain in patients with constitutional symptoms such

**TABLE 1.** Low back pain red flag signs and symptoms with associated serious pathology

| Symptoms | Corresponding pathology |
|---|---|
| Age under 18 years | Congenital abnormality |
| Age over 50 years | Fracture, malignancy |
| Anticoagulant use | Spinal hematoma |
| Fever | Infection, malignancy |
| Genitourinary issues such as urinary retention or sexual dysfunction | Cauda equina syndrome |
| Immunocompromise | Fracture, infection |
| IV drug abuse | Infection |
| Recent surgery or epidural injection | Infection, spinal hematoma |
| Trauma | Fracture, spinal hematoma |
| **Signs** | **Corresponding pathology** |
| Reduced anal sphincter tone | Cauda equina syndrome |
| Hyperreflexia | Acute cord compression |
| Hyporeflexia or areflexia | Cauda equine syndrome |
| Lower extremity muscle weakness | Acute cord compression or cauda equine syndrome |
| Saddle anesthesia | Cauda equina syndrome |



Copyright © 2020 American Academy of Physician Assistants

as fever and chills, or if physical examination reveals neurologic deficits.

**IV drug abuse** The ongoing opioid crisis in the United States has altered typical treatment regimens and created challenges for clinicians and patients. In 2016, the CDC published prescribing guidelines for opioids, which highlighted the risks of opioid prescribing.[21] The publication outlined 12 recommendations for prescribing opioids in the primary care setting.[21] Because of the guidelines, prescribing patterns changed and opioid-dependent patients were no longer being provided with opioid pain medication.[22] This may have resulted in some patients seeking alternate options, such as IV drug abuse, to control their pain.

Patients with a current or remote history of IV drug abuse are at high risk for bacteremia.[14,16,20] Recurrent bacteremia may cause hematogenous seeding of the spine, resulting in spondylodiscitis and epidural abscess.[14,16,20] Because the prescribing guidelines lead to reduced opioid prescriptions, patients with chronic pain who use illegal IV drugs may be at higher risk for spinal infections. A systematic review by Galliker and colleagues found that IV drug use was a red flag with one of the highest diagnostic accuracies for epidural abscess.[20] Perform a detailed social history, including IV drug use, when assessing patients with acute low back pain.

**Recent surgery or spinal injection** Patients may seek invasive treatments, including surgery or epidural corticosteroid injections, for chronic back pain symptoms. Although back pain may not present as acute in patients who have had recent surgery or spinal injection, changes in severity and distribution, the addition of new symptoms, or worsening of current symptoms should alert clinicians to the possibility of infection or hematoma.[8] A history of lumbar puncture may be significant and increase patient risk for epidural hematoma or infection.[14,23]

**Trauma** Major trauma (or minor trauma in older adults after a fall) in a patient with low back pain is concerning for vertebral fractures.[11] Acute spinal cord compression can occur from vertebral fractures because of nerve impingement from subluxation of vertebral bodies, bone fragments, and disk herniation.[24] In addition, trauma and anticoagulation use can result in epidural hematomas, which may present as back pain and neurologic deficits.[24]

**History of malignancy** Thoroughly screen patients for a personal history of cancer as well as for their risk of developing cancer, including family history. Although many cancers are associated with metastases, higher rates of epidural spinal cord compression are correlated with prostate, breast, and lung cancers.[18] Between 15% and 20% of patients with metastatic bone disease develop metastatic epidural spinal cord compression.[18] Symptoms reported by patients include progressive back pain over several months that may worsen with Valsalva maneuvers.[25] Localized back pain that is reproducible often results from the involvement of surrounding tissue or damaged periosteum.[25] Unexplained weight loss commonly is correlated with malignancy. Also, the presence of night or rest pain may be associated with bone cancer and should trigger clinical suspicion.[18]

**Other constitutional symptoms** Perform a complete review of systems on all patients presenting with low back pain, giving special attention to those with unexplained weight loss, night pain, or pain at rest. In general, unintentional weight loss requires a workup for malignancy; however, when it is accompanied by back pain it is particularly worrisome for metastatic disease. Night pain and pain at rest are red flags that can indicate a serious cause.[8,10] Be suspicious for infection or malignancy in patients presenting with low back pain who experience unexplained weight loss, night pain, or pain with rest.[8,10,14]

**Back pain with associated leg pain** Radiculopathy and sciatica are common symptoms experienced by patients with low back pain. Leg pain can be chronic in many patients, and by itself may not signify a red flag. However, radicular symptoms that are new or progressive, or are experienced with a combination of symptoms as previously described, warrant prompt evaluation.[24] Correlate symptoms with findings from the physical examination to determine the urgency of leg pain associated with back pain.

## RED FLAGS ON PHYSICAL EXAMINATION

For patients with chronic back pain, physical examination findings are key in identifying red flags in the acute setting as well as in comparing changes during follow-up visits. Furthermore, abnormal musculoskeletal and neurologic examination findings used in conjunction with the patient's history can identify serious pathology associated with low back pain. In general, the progression of neurologic examination results in these patients is concerning and can indicate serious pathology.[24,25]

**Motor examination** Test the strength of the patient's bilateral lower extremities to assess for weakness. In patients experiencing low back pain with radicular symptoms, 60% to 80% were found to have motor weakness because of spinal cord or nerve root compression.[25] Assess motor strength in patients with acute low back pain; this assessment also is an important tool in monitoring patients with *recurrent* low back pain. Changes in strength represent a progression of neurologic deficits, which can be a sign of urgent neurologic compromise.[26] Pathologic conditions such as cauda equine syndrome often present with saddle anesthesia; decreased anal tone is a significant concern. To evaluate anal tone, perform a digital rectal examination with distinction given to sphincter muscle tone in a relaxed versus contracted state.[27] In addition, an alteration in gait, whether normal or abnormal at baseline, in a patient with low back pain can be a sign of significant pathology.[18] Many patients with low back pain may have an altered gait because of pain, but ambulatory dysfunction may support other red-flag findings.

**Sensory examination** Sensory findings in a patient with significant spinal pathology tend to be infrequent.[25] Perform a thorough sensory examination on all patients with back



Copyright © 2020 American Academy of Physician Assistants

pain, especially when the patient reports paresthesia or hypoesthesia. An absence of sensation to light touch and pinprick can be suggestive of spinal compression and warrants additional workup.[26] Additionally, reports of saddle anesthesia necessitate sensory examination because patients with cauda equine syndrome commonly report diminished sensation.[20] The digital rectal examination that is performed as part of the motor examination also assesses anal sensation, which when decreased or absent is a pertinent finding suggestive of cauda equina syndrome.[27]

**Reflex examination** Compare reflexes bilaterally, proximally, and distally in the patient's lower extremities. Assess for hyperreflexia, which indicates an upper motor neuron lesion as seen in acute cord compression.[25,28] Hyporeflexia or areflexia are associated with lower motor neuron lesions and can present in patients with nerve root compression, as seen with cauda equina syndrome.[29] In addition, evaluate plantar reflexes; a positive Babinski reflex is a concerning finding that should alert clinicians to an upper motor neuron lesion.[25,28]

## CONCLUSION

Low back pain is a common condition. Although most low back pain cannot be attributed to a specific cause, clinicians should know which patient presentations are warning signs and symptoms of urgent or emergency conditions requiring additional evaluation. Failing to recognize these conditions in a timely manner can lead to missed or incorrect diagnoses, resulting in poor patient outcomes. Obtaining a thorough history and performing a complete physical examination will guide clinicians in recognizing red flags of low back pain. **JAAPA**

**Earn Category I CME** Credit by reading both CME articles in this issue, reviewing the post-test, then taking the online test at http://cme.aapa.org. Successful completion is defined as a cumulative score of at least 70% correct. This material has been reviewed and is approved for 1 hour of clinical Category I (Preapproved) CME credit by the AAPA. The term of approval is for 1 year from the publication date of August 2020.

## REFERENCES

1. World Health Organization. Musculoskeletal conditions. www.who.int/news-room/fact-sheets/detail/musculoskeletal-conditions. Accessed April 28, 2020.
2. Vos T, Allen C, Arora M, et al. Global, regional, and national incidence, prevalence, and years lived with disability for 310 diseases and injuries, 1990-2015: a systematic analysis for the Global Burden of Disease Study 2015. *Lancet*. 2016;388(10053):1545-1602.
3. Centers for Disease Control and Prevention. National Hospital Ambulatory Medical Care Survey: 2015 emergency department summary tables. www.cdc.gov/nchs/data/nhamcs/web_tables/2015_ed_web_tables.pdf. Accessed May 5, 2020.
4. Centers for Disease Control and Prevention. National Hospital Ambulatory Medical Care Survey: 2016 emergency department summary tables. www.cdc.gov/nchs/data/nhamcs/web_tables/2016_ed_web_tables.pdf. Accessed May 5, 2020.
5. Maher C, Underwood M, Buchbinder R. Non-specific low back pain. *Lancet*. 2017;389(10070):736-747.
6. Dubosh NM, Edlow JA, Goto T, et al. Missed serious neurologic conditions in emergency department patients discharged with nonspecific diagnoses of headache or back pain. *Ann Emerg Med*. 2019;74(4);549-561.
7. Parreira P, Maher CG, Steffens D, et al. Risk factors for low back pain and sciatica: an umbrella review. *Spine J*. 2018;18(9):1715-1721.
8. Verhagen AP, Downie A, Popal N, et al. Red flags presented in current low back pain guidelines: a review. *Eur Spine J*. 2016;25(9):2788-2802.
9. Della-Giustina D. Evaluation and treatment of acute back pain in the emergency department. *Emerg Med Clin North Am*. 2015;33(2):311-326.
10. O'Sullivan P, Smith A, Beales D, Straker L. Understanding adolescent low back pain from a multidimensional perspective: implications for management. *J Orthop Sports Phys Ther*. 2017;47(10):741-751.
11. Watts NB, Manson JE. Osteoporosis and fracture risk evaluation and management: shared decision making in clinical practice. *JAMA*. 2017;317(3):253-254.
12. Goyal G, Singh R, Raj K. Anticoagulant induced spontaneous spinal epidural hematoma, conservative management or surgical intervention—a dilemma? *J Acute Med*. 2016;6(2):38-42.
13. Tawk C, El Hajj Moussa M, Zgheib R, Nohra G. Spontaneous epidural hematoma of the spine associated with oral anticoagulants: 3 case studies. *Int J Surg Case Rep*. 2015;13:8-11.
14. Babic M, Simpfendorfer CS. Infections of the spine. *Infect Dis Clin North Am*. 2017;31(2):279-297.
15. Edlow JA. Managing nontraumatic acute back pain. *Ann Emerg Med*. 2015;66(2):148-153.
16. Kolinsky DC, Liang SY. Musculoskeletal infections in the emergency department. *Emerg Med Clin North Am*. 2018;36(4):751-766.
17. Korse NS, Pijpers JA, van Zwet E, et al. Cauda Equina Syndrome: presentation, outcome, and predictors with focus on micturition, defecation, and sexual dysfunction. *Eur Spine J*. 2017;26(3):894-904.
18. Tsuzuki S, Park SH, Eber MR, et al. Skeletal complications in cancer patients with bone metastases. *Int J Urol*. 2016;23(10):825-832.
19. Germon T, Ahuja S, Casey ATH, et al. British Association of Spine Surgeons standards of care for cauda equina syndrome. *Spine J*. 2015;15(3 suppl):S2-S4.
20. Galliker G, Scherer DE, Trippolini MA, et al. Low back pain in the emergency department: prevalence of serious spinal pathologies and diagnostic accuracy of red flags. *Am J Med*. 2020;133(1):60-72.e14.
21. Dowell D, Haegerich TM, Chou R. CDC Guideline for prescribing opioids for chronic pain—United States, 2016. *MMWR Recomm Rep*. 2016;65(No. RR-1):1-49.
22. Bonnie RJ, Schumacher MA, Clark JD, Kesselheim AS. Pain management and opioid regulation: continuing public health challenges. *Am J Public Health*. 2019;109(1):31-34.
23. Brown MW, Yilmaz TS, Kasper EM. Iatrogenic spinal hematoma as a complication of lumbar puncture: what is the risk and best management plan? *Surg Neurol Int*. 2016;7(suppl 22):S581-S589.
24. Singleton J, Edlow JA. Acute nontraumatic back pain: risk stratification, emergency department management, and review of serious pathologies. *Emerg Med Clin North Am*. 2016;34(4):743-757.
25. Yáñez ML, Miller JJ, Batchelor TT. Diagnosis and treatment of epidural metastases. *Cancer*. 2017;123(7):1106-1114.
26. Bhattacharyya S. Spinal cord disorders: myelopathy. *Am J Med*. 2018;131(11):1293-1297.
27. Todd NV. Quantifying the clinical aspects of the cauda equina syndrome—the cauda scale (TCS). *Br J Neurosurg*. 2018;32(3):260-263.
28. Ropper AE, Ropper AH. Acute spinal cord compression. *N Engl J Med*. 2017;376(14):1358-1369.
29. Rider IS, Marra EM. Cauda equina and conus medullaris syndromes. StatPearls. www.ncbi.nlm.nih.gov/books/NBK537200. Accessed May 5, 2020.



Copyright © 2020 American Academy of Physician Assistants